

Atherosclerosis Risk in Communities Study Protocol

Manual 6b

Ultrasound Assessment: Reading Procedures

Visit 3

Version 3.0

January, 1995

For Copies, Please Contact  
ARIC Coordinating Center  
Department of Biostatistics (CSCC)  
University of North Carolina  
CB# 8030, Suite 203, NationsBank Plaza  
137 E. Franklin Street  
Chapel Hill, NC 27514

## FOREWORD

This manual, entitled Ultrasound Assessment: Reading Procedures is one of a series of protocols and manuals of operation for the Atherosclerosis Risk in Communities (ARIC) Study. The complexity of the ARIC Study requires that a sizeable number of procedures be described, thus this rather extensive list of materials has been organized into the set of manuals listed below. Manual 1 provides the background, organization, and general objectives of the ARIC Study. Manuals 2 and 3 describe the operation of the Cohort and Surveillance Components of the study. Detailed Manuals of Operation for specific procedures, including those of reading centers and central laboratories, make up Manuals 4 through 11 and 13 through 15. Manual 12 on Quality Assurance contains a general description of the study's approach to quality assurance as well as the details for quality control for the different study procedures.

### ARIC Study Protocols and Manuals of Operation

<u>MANUAL</u>	<u>TITLE</u>
1	General Description and Study Management
2	Cohort Component Procedures
3	Cohort and Community Surveillance
4	Pulmonary Function Assessment - (Retired)
5	Electrocardiography
6	Ultrasound Assessment <ul style="list-style-type: none"><li>a. Ultrasound Scanning Procedures</li><li>b. Ultrasound B-mode Image Reading Protocol</li><li>c. Distensibility Scanning Protocol - (Retired)</li><li>d. Distensibility Reading Protocol - (Retired)</li></ul>
7	Blood Collection and Processing
8	Lipid and Lipoprotein Determinations
9	Hemostasis Determinations
10	Clinical Chemistry Determinations - (Retired)
11	Sitting Blood Pressure
12	Quality Assurance and Quality Control
13	Magnetic Resonance Imaging <ul style="list-style-type: none"><li>a. Magnetic Resonance Imaging Protocol</li><li>b. Magnetic Resonance Imaging Reading Protocol</li></ul>
14	Retinal Photography
15	Echocardiography

MANUAL 2  
TABLE OF CONTENTS

1.	INTRODUCTION . . . . .	1
2.	SUMMARY OF DATA FLOW WITHIN THE URC . . . . .	2
3.	READER TRAINING AND ASSIGNMENTS . . . . .	4
	3.1 Training . . . . .	4
	3.2 Monitoring . . . . .	6
	3.3 Recertification . . . . .	6
	3.4 Continuing Education . . . . .	7
	3.5 Reader Assignments . . . . .	7
	3.6 Quality Control process for Readers . . . . .	7
4.	READER WORK STATION INSTRUMENTATION . . . . .	10
	4.1 General Description . . . . .	10
	4.2 Specifications . . . . .	10
5.	READING OF ULTRASONIC B-MODE IMAGES . . . . .	15
	5.1 Orientation to the Biosound B-mode Image . . . . .	15
	5.2 Arterial Sites to be Examined . . . . .	15
	5.3 Definition of Important Tissue Interfaces Within the Normal Arterial Wall . . . . .	17
	5.4 Physical Principles of B-mode Image Formation . . . . .	19
	5.5 Identification of Principal Boundaries from the B-mode Images . . . . .	24
	5.6 Calibration of Image Pixel Size . . . . .	24
	5.7 Procedure for Reporting Alert Values . . . . .	24
	5.8 Placement of Crosshairs on Principal Boundaries . . . . .	25
6.	OPERATION OF THE READER STATION . . . . .	36
	6.1 Equipment Start-up and Login . . . . .	36
	6.2 Transfer of Participant Files from the Central Computer . . . . .	36
	6.3 The Image Measurement System . . . . .	36
	6.4 The Database Screen . . . . .	38
	6.5 Ending the Reading Session . . . . .	39
7.	URC QUALITY CONTROL PROGRAM FOR BIOSOUND INSTRUMENTS . . . . .	40
	7.1 Instrumentation . . . . .	40
	7.2 Reader . . . . .	40
	7.3 Phantom Scan Data Flow . . . . .	40
	7.4 Phantom Scan Videocassette Flow . . . . .	40
	7.5 Phantom Scan Evaluation . . . . .	40
	7.6 Phantom Signal Strength Measurements . . . . .	42
8.	QUALITY ASSURANCE PROGRAM . . . . .	48
	8.1 Introduction . . . . .	48
	8.2 Process Control Charts . . . . .	48
	8.3 Special Studies . . . . .	51
	8.4 Frequency . . . . .	51
	8.5 QA reports . . . . .	51
	8.6 Readers . . . . .	51
	8.7 Reports to the Quality Control Committee . . . . .	52

**APPENDIX I: EXERCISES FOR READING B-MODE IMAGES . . . . . A - 1**  
Exercise 1 Right Common Carotid: Figures 21 and 22 . . . . . A - 1  
Exercise 2 Right Common Carotid: Figures 23 and 24 . . . . . A - 4  
Exercise 3 Right Common Carotid: Figures 25 and 26 . . . . . A - 7  
Exercise 4 Right Common Carotid: Figures 27 and 28 . . . . . A - 10  
Exercise 5 Right Common Carotid: Figures 29 and 30 . . . . . A - 13  
Exercise 6 Right Common Carotid: Figures 31 and 32 . . . . . A - 16  
Exercise 7 Right Common Carotid: Figures 33 and 34 . . . . . A - 19  
Exercise 8 Right Internal Carotid: Figures 35 and 36 . . . . . A - 22  
Exercise 9 Left Common Carotid: Figures 37 and 38 . . . . . A - 25  
Exercise 10 Left Common Carotid-Optimal: Figures 39 and 40 . . . . . A - 28  
Exercise 11 Left Carotid Bulb: Figures 41 and 42 . . . . . A - 31  
Exercise 12 Left Carotid Bulb: Figures 43 and 44 . . . . . A - 34  
Exercise 13 Left Carotid Bulb: Figures 45 and 46 . . . . . A - 37

**APPENDIX II: READING LIST . . . . . A - 40**

## LIST OF FIGURES

Figure 1	Ultrasound Reading Center Flow Chart . . . . .	3
Figure 2	Reader Sheet . . . . .	9
Figure 3	sVHS PC-VCR - Rear Panel . . . . .	11
Figure 4	486 PC - Rear Panel . . . . .	12
Figure 5	Panasonic 19" Color Monitor Model 2010Y - Rear Panel . . . . .	13
Figure 6	Truevision VidI/O Box - Rear Panel . . . . .	14
Figure 7	Geometry of B-mode Images . . . . .	26
Figure 8	Diagram of the Arterial Tree . . . . .	27
Figure 9	Simplified Diagrams of the B-mode Images to be Read . . . . .	28
Figure 10	Diagram of the Arterial Wall Layers . . . . .	29
Figure 11	Idealized B-mode Image of a Single Boundary . . . . .	30
Figure 12	Idealized B-mode Image of Two Boundaries . . . . .	31
Figure 13	Idealized B-mode Image of Boundaries Simulating Arterial Walls . . . . .	32
Figure 14	Idealized B-mode Image of Boundaries Simulating Arterial Walls . . . . .	33
Figure 15	Biosound Calibration Frame for Determination of Image Pixel Size . . . . .	34
Figure 16	Place of Crosshairs on B-mode Image Boundaries . . . . .	35
Figure 17	Phantom Measurement Sheet . . . . .	44
Figure 18	Phantom Measurement - Arterial Signal Strengths . . . . .	45
Figure 19	Phantom Log Sheet . . . . .	46
Figure 20	Phantom Cassette Labels . . . . .	47
Figure 21	B-mode Image of Right Common Carotid . . . . .	A - 2
Figure 22	B-mode Image of Right Common Carotid: Detail of B-mode Image . . . . .	A - 3
Figure 23	B-mode Image of Right Common Carotid Artery . . . . .	A - 5
Figure 24	B-mode Image of Right Common Carotid: Detail of B-mode Image . . . . .	A - 6
Figure 25	B-mode Image of Right Common Carotid . . . . .	A - 8
Figure 26	B-mode Image of Right Common Carotid: Detail of B-mode Image . . . . .	A - 9
Figure 27	B-mode Image of Right Common Carotid . . . . .	A - 11
Figure 28	B-mode Image of Right Common Carotid: Detail of B-mode Image . . . . .	A - 12
Figure 29	B-mode Image of Right Common Carotid . . . . .	A - 14
Figure 30	B-mode Image of Right Common Carotid: Detail of B-mode Image . . . . .	A - 15
Figure 31	B-mode Image of Right Common Carotid . . . . .	A - 17
Figure 32	B-mode Image of Right Common Carotid: Detail of B-mode Image . . . . .	A - 18
Figure 33	B-mode Image of Right Common Carotid . . . . .	A - 20
Figure 34	B-mode Image of Right Common Carotid: Detail of B-mode Image . . . . .	A - 21
Figure 35	B-mode Image of Right Internal Carotid . . . . .	A - 23
Figure 36	B-mode Image of Right Internal Carotid: Detail of B-mode Image . . . . .	A - 24
Figure 37	B-mode Image of Left Common Carotid . . . . .	A - 26
Figure 38	B-mode Image of Left Common Carotid: Detail of B-mode Image . . . . .	A - 27
Figure 39	B-mode Image of Left Common Carotid-Optimal . . . . .	A - 29
Figure 40	B-mode Image of Left Common Carotid-Optimal: Detail of B- mode Image . . . . .	A - 30

Figure 41 B-mode Image of Left Carotid Bulb . . . . . A - 32  
Figure 42 B-mode Image of Left Carotid Bulb: Detail of B-mode Image A - 33  
Figure 43 B-mode Image of Left Carotid Bulb . . . . . A - 35  
Figure 44 B-mode Image of Left Carotid Bulb: Detail of B-mode Image A - 36  
Figure 45 B-mode Image of Left Internal Carotid . . . . . A - 38  
Figure 46 B-mode Image of Left Internal Carotid: Detail of B-mode  
Image . . . . . A - 39

## 1. INTRODUCTION

The participant data acquired at the ultrasound work station within each field center are analyzed at a central reading facility located at the Ultrasound Reading Center (URC) in Winston-Salem, North Carolina. The data include B-mode images, arterial distensibility data and blood pressure data. The data are forwarded to the URC from each field center at weekly intervals in the form of 1/2" s-VHS cassette tapes and 3 1/2" floppy disks. After analyses, data summaries are sent from the URC to the Coordinating Center.

This protocol describes the detailed procedures used in reading the ultrasound B-mode images at the URC. Figures referred to in each section are numbered to correspond with sections in which they are cited.

## 2. SUMMARY OF DATA FLOW WITHIN THE URC

Data flow within the URC is summarized in Figure 1. The video cassettes (VC) and the floppy disks (FD) received from each of the four field centers are checked in upon their arrival at the URC. Package contents are verified against the login sheet for completeness. The video cassettes containing the participant ultrasound scans and the floppy disks containing participant information and distensibility data are logged into the computer.

When this has been completed, the floppy disks and the video cassettes are routed to the librarian who enters the video cassette and floppy disk number into the library system. The video cassettes and floppy disks are then placed into the reading queue.

The chief reader uses the participant identification numbers in the computer to generate randomly selected reading assignments and quality assurance assignments for the readers. These assignment sheets are posted in the readers' files along with the corresponding video cassette number.

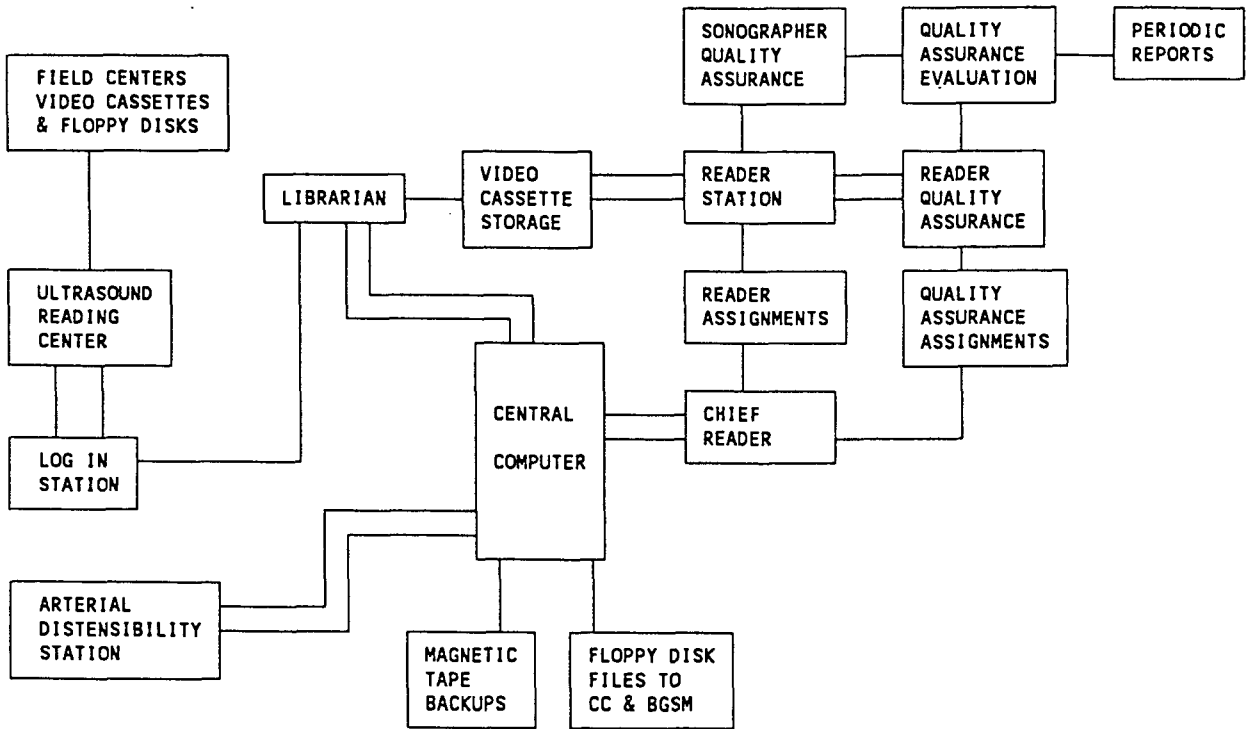
The readers retrieve their assignment sheets. The video cassettes and the floppy disks are checked out from the reading queue and taken to the reading station. Frames from each arterial site are selected and crosshairs are placed along the appropriate interfaces for each site. The reading data are checked for programming and interface assignment errors at the reading station. Data are sent to the central computer when all errors, if any, are corrected.

Once a participant study has been read, the sVHS cassette and the floppy disk are returned to the reading queue. The reading process is continued until all the participant studies on the video cassette have been read. The video cassette and the floppy disk are then placed in the long term cassette storage area.

On occasion it will be necessary to review data on a stored video cassette. The cassettes and floppy disks in long-term storage are available for review and can be checked out for additional studies by authorized personnel.



Figure 1 Ultrasound Reading Center Flow Chart



### 3. READER TRAINING AND ASSIGNMENTS

#### 3.1 Training

The reader training program includes training sessions held at the Ultrasound Reading Center, followed by practice readings and certification steps at the Ultrasound Reading Center.

##### 3.1.1 Stage 1

During the initial weeks, a new reader works with Study certified readers to observe the ultrasound reading area activities, become familiar with the equipment, read the introductory material supplied by the URC, and become familiar with this reading protocol.

##### 3.1.2 Stage 2

The second phase (40 hours) at the Ultrasound Reading Center consists of lectures, demonstrations, and practical laboratory experience on the following topics:

- a. Overview of the study.
- b. Role of the Ultrasound Reading Center.
- c. Ultrasonic Physics I, including basic physics concepts, units of measurement, and mathematics arising in the medical applications of ultrasound.
- d. Overview of atherosclerosis and a detailed discussion of the normal artery wall.
- e. Ultrasonic Physics II, including a discussion of the properties of ultrasonic waves, reflection at boundaries and scattering from small objects.
- f. Ultrasonic Physics III, including the Doppler effect, ultrasound transducers and sound beams.
- g. Pathology of Atherosclerosis.
- h. Principles of Ultrasonic Instrumentation, including pulse-echo imaging systems, pulsed Doppler systems, and spectral analysis.
- i. Basic operation of the Biosound Phase 2.
- j. Instrument Performance.
- k. Principles of Ultrasound Arterial Scanning.

The remaining central training time (15 hours) will be spent learning the reading program and the reading protocol. The new reader will then practice reading 25 participant studies. These readings are done under the direct supervision of the chief reader who guides, evaluates, offers suggestions for improvements, and answers questions as they arise. Each reading is reviewed with the new reader, and strengths and weaknesses are identified. The reading results produced by the new reader are compared to a certified reader's reading results to determine the new reader's progress. The chief reader determines when the new reader is ready for precertification.

##### 3.1.3 Stage 3

When the chief reader determines the new reader is ready for precertification, the new reader is assigned at least two batches of 25 readings each to read. The first batch will provide the reader experience in reading studies with the simplest images. The second batch of studies provides the reader with

experience in reading the more complicated images and encompasses most imaging situations involved in the reading process.

The chief reader uses a SAS computer program to compare readings from the new reader with those of certified readers for the same studies. Any reading differences in frame selection, boundary identification or wall thickness measurements are reviewed with the new reader.

An evaluation batch of studies will then be assigned to the new reader. When the chief reader is satisfied that the new reader's reading results comply with standards of quality, of systolic frame selection, interface identification, measurement of arterial wall within the ultrasound image and overall quality of reading process, the chief reader notifies the URC project manager that the reader has completed the supervised reading phase and is certified.

### 3.2 Monitoring

The chief reader reviews one study per month for all readers. The primary purpose in reviewing these studies is to ensure the quality of the study data and adherence to the reading protocol. The secondary purpose is to check for comparable frame selection and interpretation results which provide repeatable, precise measurement of the arterial wall interfaces.

### 3.3 Recertification

#### 3.3.1 Recertification

Readers are recertified whenever change to the reading process is implemented. Five studies are reviewed and evaluated. They must meet the new standards for recertification.

#### 3.3.2 Lapsed Certification

##### 3.3.2.1 Absent less than two months or not maintaining minimum number of required studies (10/month averaged over two months):

- a. the chief reader updates the reader on any changes in procedures;
- b. the first five readings done by the reader are done under direct supervision of the chief reader, reviewed by the chief reader;
- c. the monthly review of a randomly selected study read by the chief reader resumes and/or continues.

##### 3.3.2.2 If reader is absent 2 or more months

- a. The chief reader updates the reader on any changes in procedures;
- b. the reader observes a minimum of five studies being read by a certified reader;
- c. the first five readings done by the reader are done under direct supervision of the chief reader, reviewed by the chief reader;
- d. when the chief reader determines the studies are read according to current protocol and meet quality standards, the reader is recertified.

When a reader is recertified, the project manager is notified.

The URC chief reader is responsible for precertification, certification and recertification of readers. All these certifying processes primarily involve reviewing and evaluation of readings done by the readers.

### **3.4 Continuing Education**

#### **3.4.1 Monthly Technical Meeting**

The chief reader reviews the reading results from the monthly inter/intra studies read. Any differences in the reading process is reviewed with all readers by observing the images in question and discussing the reading process for the given image.

#### **3.4.2 Stump of the Month**

Complicated images are selected by the chief reader and discussed with the readers once a month. This review provides the readers with other readers' insight on how to interpret the images for reading.

### **3.5 Reader Assignments**

A computer program is run weekly at the Ultrasound Reading Center which does the following:

- a. Randomizes and assigns transcribed studies. The number of reader assignments are weighted according to the total weekly studies read by each reader.
- b. Assigns Inter QC studies.
- c. Assigns Intra QC studies.
- d. Formats and sends a file to the printer containing all the information needed to read the studies assigned. (Figure 2).

### **3.6 Quality Control process for Readers**

A computer-controlled assignment program assigns three quality control studies in addition to assigning routine reading assignments.

- a. Inter QC: one study assigned to two readers. This checks for variability between readers.
- b. Intra QC: one study assigned to one reader at different times. This checks for variability of results.
- c. All Reader QC: one study chosen by the chief reader and assigned to all readers. This checks variability between all readers on one study.

Statistics are reviewed quarterly to monitor the performance of individual readers as well as the entire reader group. Trends suggesting a deterioration in performance levels are promptly discussed with the individuals concerned in order to correct deficiencies as soon as possible. Sustained high performance levels during the studies are recognized and commendation and incentives provided to the individuals involved.

## Figure 2 Reader Sheet

X164114

X164114

VISIT 3

Type of study 1

Reader number 31

Tape Id Number F12934J  
2150

012	02159	02171	Start Code and Calibration			
048	02342	02354	Common	Right	B-mode	Optimal
080	02382	02394	Bulb	Right	B-mode	Optimal
112	02413	02425	Internal	Right	B-mode	Optimal
084	02442	02454	Bulb	Right	B-mode	Far Wall
092	02469	02481	Bulb	Right	B-mode	Near Wall
032	02702	02714	Common	Left	B-mode	Optimal
064	02765	02777	Bulb	Left	B-mode	Optimal
032	02798	02810	Common	Left	B-mode	Optimal
096	02837	02849	Internal	Left	B-mode	Optimal
068	02876	02888	Bulb	Left	B-mode	Far Wall
076	02918	02930	Bulb	Left	B-mode	Near Wall

#### 4. READER WORK STATION INSTRUMENTATION

##### 4.1 General Description

The instrumentation provided at each B-mode image analysis work station includes a personal computer (PC) with computer monitor, a frame grabber card, a color TV monitor and an sVHS video cassette recorder (VCR). The reader selects specific image frames from the video tape and acquires these image frames using the PC. The detailed reader protocol for making measurements is completed on these frames, and a data file on each participant is stored on the hard disk of the PC. After participant data have been stored on the PC hard disk and checked for boundary errors and unusual wall thickness, these data are transmitted to the URC central computer for storage, analyses, and preparation of data summaries which are forwarded to the Coordinating Center.

##### 4.2 Specifications

The equipment used for this study is as follows:

NEC 1/2" pc sVHS PC-VCR

100% IBM compatible 33MHz 486 personal computer with -  
- 101 enhanced keyboard  
- 1 MB RAM  
- 120 MB hard drive  
- Vista frame grabber card  
- DOS 5.0 or higher

Panasonic 19" Color Monitor - Model CT 2010Y (or equivalent)

Truevision VidI/O Box

The reader should, as part of her training read, understand and follow the instruction manuals provided with this equipment.

See Figures 3-6 for cabling specifications. These diagrams are designed to display settings and identify cabling connections on each piece of equipment.



Figure 3 sVHS PC-VCR - Rear Panel

Outputs to Video/Box  
S-Video Input

Outputs to Monitor  
Line B "IN"

Output to Computer

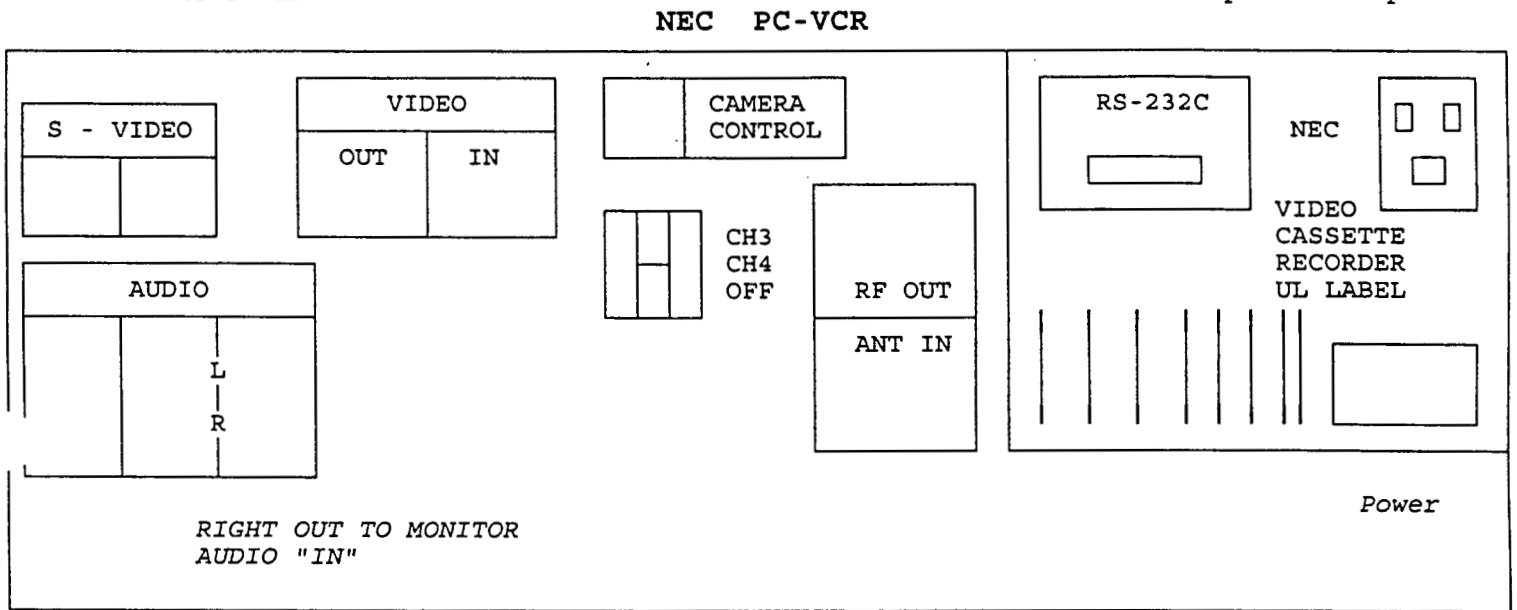


Figure 4 486 PC - Rear Panel

TOWER COMPUTER-PC 486  
FACING REAR PANEL

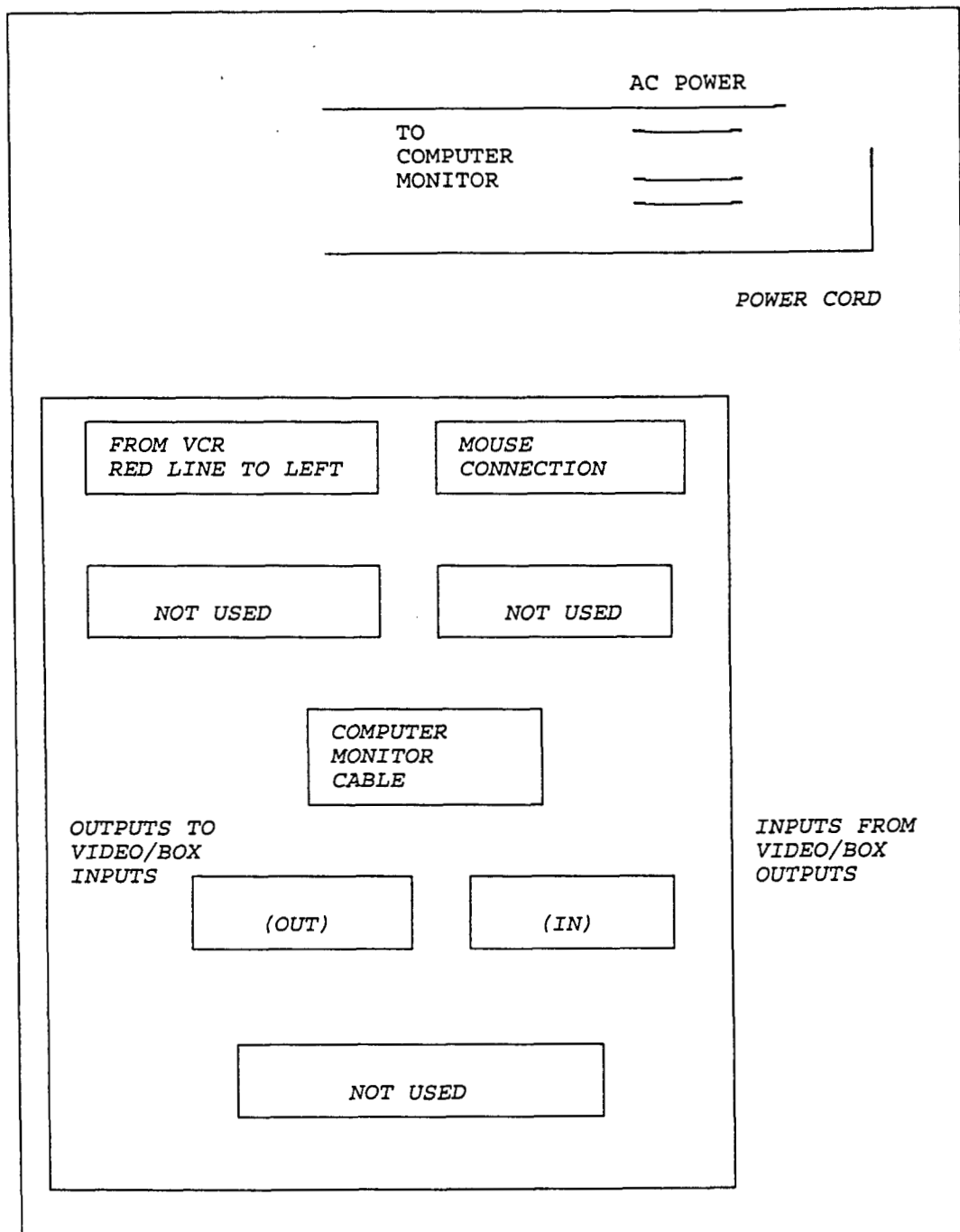
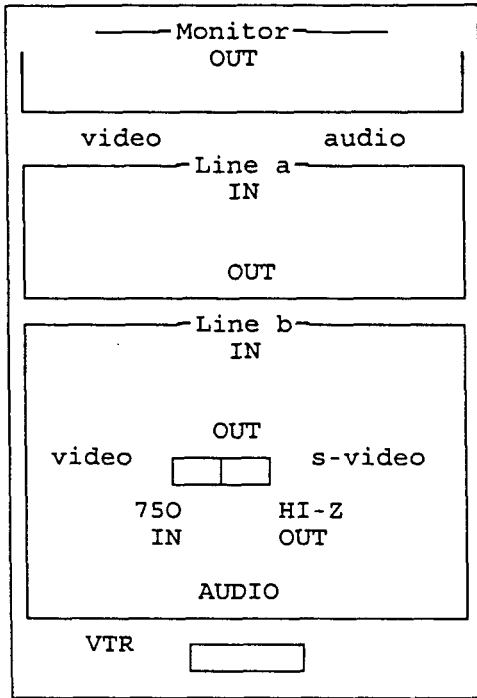


Figure 5 Panasonic 19" Color Monitor Model 2010Y - Rear Panel



Input from VID I/O box (video output)

Input from VCR (video out)

Input from VCR (right audio "out")

POWER CORD

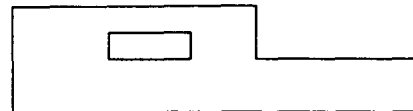
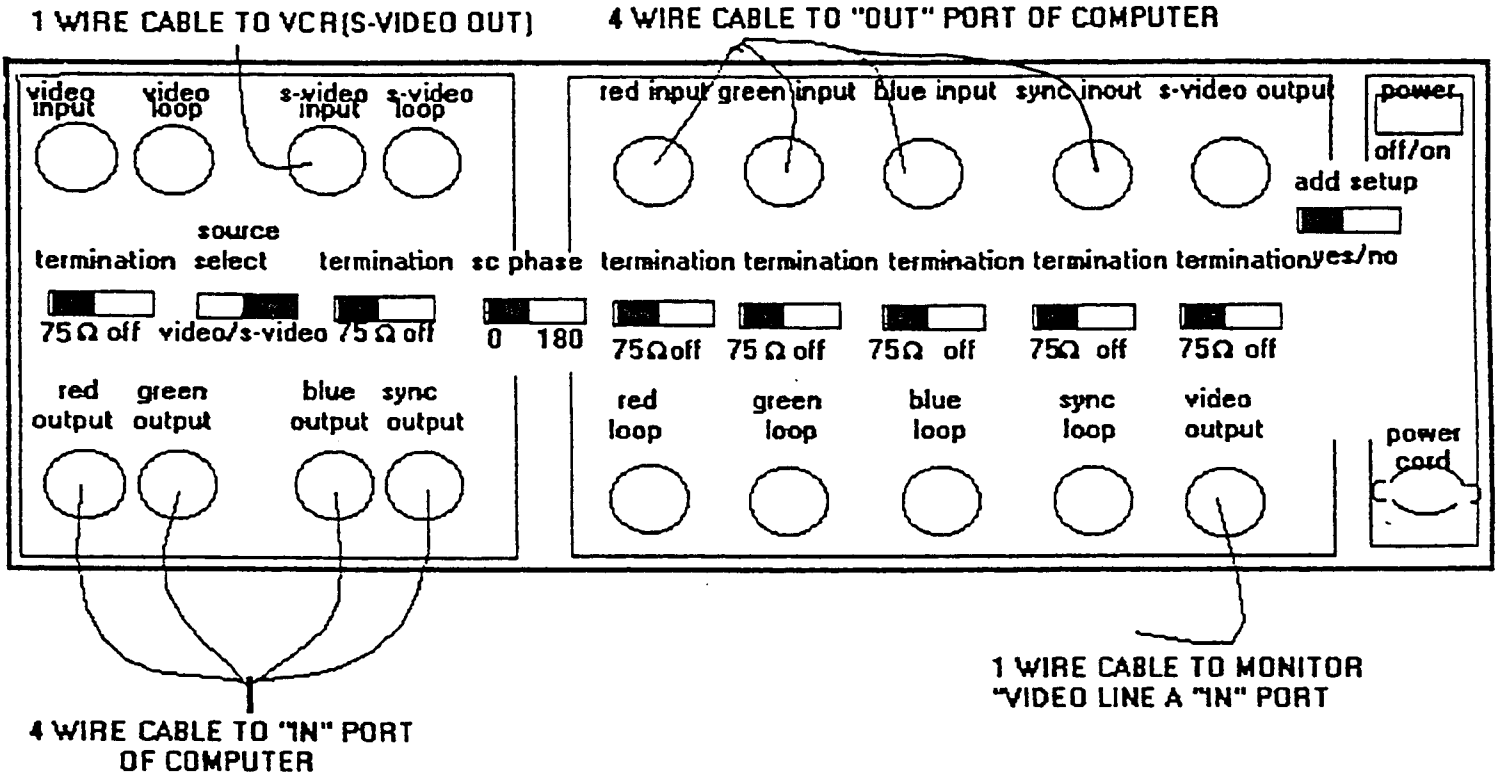


Figure 6 Truevision VidI/O Box - Rear Panel



REAR PANEL

## 5. READING OF ULTRASONIC B-MODE IMAGES

### 5.1 Orientation to the Biosound B-mode Image

The B-mode image appearing on the Biosound video screen shows a rectangular segment of the tissues at and below the skin surface having the dimensions shown in Fig. 7. The transducer in contact with the skin surface is located along the left side of the rectangle. Deeper structures are located at successively greater distances from left to right across the image. The deepest structures which can be imaged are located 4 cm from the skin surface. The width of the tissue segment visible is 2 cm.

### 5.2 Arterial Sites to be Examined

#### 5.2.1 Introduction

B-mode images are obtained at three anatomical sites (the distal common, the bulb, and the internal carotid) in each of the left and right carotid arteries in the neck. Simplified diagrams of the anatomical sites and the various images which are obtained on each participant are shown in figures 8 and 9. The arteries are scanned at the optimal interrogation angle defined as the orientation of the transducer handle at which the two principal anatomical landmarks (the origin of the bulb and the most superior portion of the arc of the flow divider (Fig. 8) are visualized.

#### 5.2.2 Carotid Arteries

The right and left carotid arteries are located between the clavicle and the base of the skull on each side of the neck. The common carotid normally bifurcates (divides) into two arteries (the internal carotid and external carotid) at or near the level of the larynx.

##### 5.2.2.1 The Right Common Carotid Artery

When the right common carotid image is obtained, the optimal angle defined in Section 5.2.1 will be used to interrogate the vessel and obtain separate images. The origin of the crest of the bulb is the principal anatomical landmark to be identified. The cursor should always be placed at the level of the origin of the bulb by the sonographer who is able to define this point, even when the origin cannot be seen on the reader's image. Measurements are made on the 10mm segment of the common carotid artery immediately below this landmark on the image. This arterial segment is usually located between 2 cm and 3 cm below the skin surface and is generally shallowest when imaged from the anterior angle and deepest when imaged from the posterior angle.

Frame selection is determined by: (listed by priority)

1. Systolic frame
2. Best visualized boundary 5, 2, 4, 3 - prioritized in this order

##### 5.2.2.2 The Right Carotid Artery Bulb

The next image acquired is that of the right carotid bulb, using only the optimal transducer angle. The superior arc of the flow divider separating the internal and external carotid arteries is the principal anatomical landmark to be identified in the image. The cursor should be located by the sonographer at this position in the image also. Measurements are made on the 10 mm

segment of the bulb directly below this landmark on the image. The segment is generally located about 2 cm - 3 cm below the skin surface.

Frame selection is determined by: (listed by priority)

1. Systolic frame
2. Best visualized boundary 5, 2, 4, 3 - prioritized in this order

#### 5.2.2.3 The Right Internal Carotid Artery

The next image acquired is that of the right internal carotid artery, using only the optimal transducer angle. The superior arc of the flow divider is again the principal anatomical landmark identified and marked with the cursor. Measurements will be made on the 10mm segment of the internal carotid directly above this landmark on the image. The segment is usually nearer to the skin surface than the external carotid and has a larger diameter.

Frame selection process is determined by priority.

- Best visualization of boundaries - 5, 4, 2, 3 - prioritized in this order

#### 5.2.2.4 The Right Carotid Artery Bulb - Far Wall Only

The next image acquired is that of the far wall only of the right carotid bulb. The method is identical to that described in 5.2.2.2 except that the primary objective is to acquire very high quality images of far wall boundaries only.

Frame selection is determined by best visualized boundary 5, then 4.

#### 5.2.2.5 The Right Carotid Artery Bulb - Near Wall Only

The next image acquired is that of the near wall only of the right carotid bulb. The method is identical to that described in 5.2.2.2 except that the primary objective is to acquire very high quality images of the near wall boundaries only.

Frame selection is determined by best visualized boundary - 2, then 3.

#### 5.2.2.6 The Left Common Carotid Artery

The left common carotid is studied in a manner identical to that of the right common carotid. The image is inverted compared to the right side, with the participant's head located at the bottom of the image. Measurements are made on the 10 mm segment of the artery above the origin of the crest of the bulb, as seen on the image monitor.

Frame selection is determined by: (listed by priority)

1. Systolic frame
2. Best visualized boundary 5, 2, 4, 3 - prioritized in this order

#### 5.2.2.7 The Left Carotid Artery Bulb

The left carotid bulb is studied in a manner identical to that of the right carotid bulb. Again, the image is inverted compared to the right side, with the participant's head located at the bottom of the image. Measurements are

made on the 10 mm segment of the bulb directly above the origin of the flow divider as seen on the image monitor.

Frame selection is determined by: (listed by priority)

1. Systolic frame
2. Best visualized boundary 5, 2, 4, 3 - prioritized in this order

#### 5.2.2.8 The Left Internal Carotid Artery

The left internal carotid artery is studied in a manner identical to that of the right internal carotid. This image is also inverted compared to the right side, as discussed in 5.2.2.4 and 5.2.2.5. Measurements are made on the 10 mm segment of the artery directly below the superior arc of the flow divider as seen on the image monitor.

Frame selection process is determined by priority.

- Best visualization of boundaries - 5, 4, 2, 3 - prioritized in this order

#### 5.2.2.9 The Left Carotid Artery Bulb - Far Wall Only

The next image acquired is that of the far wall only of the left carotid bulb. The method is identical to that described in 5.2.2.7 except that the primary objective is to acquire very high quality images of far wall boundaries only.

Frame selection is determined by best visualized boundary 5, then 4.

#### 5.2.2.10 The Left Carotid Artery Bulb - Near Wall only

The next image acquired is that of the near wall only of the left carotid bulb. The method is identical to that described in 5.2.2.7 except that the primary objective is to acquire very high quality images of the near wall boundaries only.

Frame selection is determined by best visualized boundary - 2, then 3.

### 5.3 Definition of Important Tissue Interfaces Within the Normal Arterial Wall

#### 5.3.1 Tissue Layers Within the Normal Artery Wall

Three distinct anatomic layers are identified in the walls of normal arteries: the tunica intima, tunica media and tunica adventitia. A simplified diagram of these layers is shown in Fig. 10 for a normal arterial wall.

The innermost of the three layers which is directly adjacent to the blood is the intima. In a normal artery, this is a relatively thin region measuring less than 0.10 mm. This is less than one-tenth of the total arterial wall thickness. With the development of lesions, this layer may expand greatly and become the thickest layer within the artery wall. Generally, over 90% of the normal intima plus media thickness is composed of the media. The media varies widely in thickness, depending on the arterial segment, and in composition, depending on whether the components are primarily characterized by elastic tissue, smooth muscle cells, or a combination of these tissues. With the development of lesions, the intima may involve the media and significantly modify its thickness and characteristics.

The outermost portion of the arterial wall is the adventitia. The adventitia begins at the outermost region of the media, defined anatomically as the external elastic lamina, and is composed principally of collagen, a dense form of connective tissue, with small nerve fibers, vessels and elastic fibers also being present. The thickness of the adventitia varies, depending on the particular artery segment and its location within the cardiovascular system. The outermost portion of the adventitia is bounded by periadventitial adipose tissue which may vary in thickness. It gradually merges into the surrounding tissue (periadventitial tissue). Its outer boundary is not generally well-defined. With severe disease present, plaque may protrude into and involve the adventitia.

### 5.3.2 Tissue Boundaries Associated With the Normal Artery Wall

The ultrasound study uses the four interfaces marked with a (\*) below, that serve as boundaries and which are most easily identified in straight segments of longitudinal B-mode ultrasound arterial images. The overall goals of the ultrasound component of ARIC are the valid and reliable measurement of distances between these interfaces, including lumen diameter and (intima + media) thicknesses, as well as other linear and area measurements.

- 1 - Boundary between the periadventitia and adventitia of the near wall
- \*2 - Boundary between the adventitia and media of the near wall
- \*3 - Boundary between the intima of the near wall and the blood
- \*4 - Boundary between blood and intima of the far wall
- \*5 - Boundary between media and adventitia of the far wall
- 6 - Boundary between adventitia and periadventitia of the far wall

The following sections discuss procedures for identifying these boundaries from B-mode images and measuring their locations. Pay particular attention to the difference in the interpretation of boundary 2 relative to boundaries 3, 4 and 5, in terms of the physical principles involved in obtaining B-mode images of closely spaced interfaces.



## 5.4 Physical Principles of B-mode Image Formation

### 5.4.1 The Pulse-Echo Principle

Ultrasonic B-mode images are obtained by sending out short, narrow bursts of acoustical energy and receiving echoes which arise from the environment. The energy is assumed to travel in a straight line until encountering a reflecting object. Echoes received are assumed to originate from reflectors located in a specific direction defined by the direction of the ultrasonic beam. After echoes arrive, the time between the transmission and reception is electronically measured and assumed to be proportional to the distance of the reflector from the source of the energy. Assuming an average sound velocity along the propagation path, an absolute distance to the target can be calculated. After converting the acoustical echoes into electrical signals, the amplitudes of these signals are used to modulate the brightness of an electron beam on a video display. This process produces an image of the plane through which the sound transducer scans. This image is referred to as a B-mode (Brightness mode) image. See Appendix I - Figures 21-46.

### 5.4.2 The Origin of Echoes

Reflections originate, in general, whenever an acoustic wave passes from one material into another. If the mechanical properties (stiffness x mass density) of the two materials differ greatly, a strong reflection occurs at the boundary and only a small amount of energy passes through. If the mechanical properties are very similar, a very weak reflection occurs and most of the energy passes through. It is possible for rather different materials to have very similar mechanical properties so that the amplitude of the reflection is negligible. In such a case, a pulse-echo system would not detect the presence of the boundary. Consequently, B-mode images may fail to visualize certain boundaries located within the scan plane.

An optical analogy exists. When a first quality plate glass window is very clean, it is difficult to see its surfaces even when bright daylight is available to be reflected from these surfaces. This situation has on rare occasion resulted in a person injuring himself attempting to walk through such a plate. The mechanical properties of glass and air are very different but the factors producing optical reflection are such that the surfaces are invisible to the eye. Interpretation of anatomical information contained on B-mode images should be approached with a similar healthy skepticism.

### 5.4.3 Reflection From Smooth, Flat Boundaries

When a narrow beam of energy strikes a smooth flat boundary perpendicular to its path, it returns along the same path. In a pulse-echo imaging system, an echo is received from such a boundary, assuming that the mechanical properties across the boundary are sufficiently different. However, if the angle of incidence differs by only a few degrees from being perpendicular, the reflection may be missed. Consequently, the slightly oblique or curvilinear smooth boundary may not be seen on the image even though it is present.

### 5.4.4 Reflection From Rough Boundaries

When a ray of energy strikes a rough boundary from almost any direction, energy is scattered over a broad range of angles. Such a boundary is normally visualized on pulse-echo images since the source is likely to receive at least

a small portion of the scattered energy. Rough boundaries are relatively insensitive to slight changes in ultrasonic propagation angle.

#### 5.4.5 Imaging of Arterial Wall Boundaries

A boundary is located on a B-mode image as a dark to bright transition going from shallow to deep structures. This transition identifies the BEGINNING of the return echo and its position is relatively insensitive to the echo strength or instrument gain setting. The bright to dark transition at the end of the echo is determined by other factors including the echo strength and system gain settings. This is discussed in detail in Section 5.4.8.

When sound is traveling from the center (lumen) of a normal artery outward through a wall, it passes through several principal boundaries: the blood-intima boundary; the intima-media boundary; the media-adventitia boundary, and the adventitia-periadventitia boundary. In the absence of disease, the blood-intima boundary is rather smooth. Thus reflections are very angle dependent. In addition, the mechanical properties of the media are quite similar and the reflections are relatively weak. Consequently, it is not uncommon for the blood-intima boundary to be very faint or nearly invisible on pulse-echo images.

As the surface becomes irregular (rougher) due to disease development, the sensitivity to angle diminishes. Also, the mechanical properties of lesions may become significantly different from the blood and therefore result in larger amplitude echoes. Consequently, this boundary is more likely to be visible on the image after disease develops. Inability to visualize the boundary tends to suggest a normal artery if considerable effort has been made by the sonographer to visualize the boundary.

Since the normal intima is generally considerably thinner than 0.10 mm, the echoes from the blood-intima and intima-media interfaces tend to overlap when they are present. Consequently, the location of the intima-media boundary cannot usually be resolved in normal artery walls. As the intima thickens as a result of disease, the location of the intima-media boundary may be visualized. Generally this occurs when thickness is greater than 0.20 mm; although, should the mechanical properties of the intima and adjacent media be very similar, this interface may still not be seen.

The normal media in the carotid arteries is between 0.6-1.0 mm in thickness, and the media-adventitia boundary can generally be resolved with a high resolution ultrasound system. This boundary is usually rougher, produces strong reflections and is readily visualized on pulse-echo images.

The adventitial tissue is generally heterogeneous, containing collagen, nerve fibers, vessels, etc., and normally in the order of 0.2mm thick. Many relatively rough boundaries are present within this region and consequently the adventitia-periadventitia boundary may be difficult to resolve. Echoes from within the adventitia overlap echoes which arise at this boundary on the far wall. The location of the adventitia- periadventitia boundary can on occasion be estimated by observing the apparent end of the echoes arising from this interface and then subtracting an echo pulse length from it.

In summary, when imaging from the blood outward, i.e., far wall, in normal vessels, the normal blood-intima (boundary 4) and media- adventitia (boundary 5) interfaces are seen with clarity and are generally resolvable. The former

is often nearly invisible in young, normal subjects, whereas the latter is usually seen. With the development of disease, both tend to be readily visualized.

If we now consider the boundaries encountered by a sound pulse as it enters an artery from the outside, we can expect the following differences. The periadventitia-adventitia interface on the near wall appears highly reflective, and therefore can on occasion be demonstrated in B-mode images even when gain settings are relatively low. The easiest angle for reliably identifying this boundary is anterior. As the angle of interrogation becomes more lateral, the internal jugular vein is seen in front of the carotid artery, with the far wall of the vein adjacent to the near wall of the artery. When this vein-artery relationship is present, it is often difficult to reliably identify the arterial periadventitial-adventitial interface. Strong echoes from the adventitia tend to overlap the adventitia-media boundary. The boundary which is relatively easy to identify in the normal near wall is the media-intima interface. Because the normal intima is very thin, this is an excellent approximation of the intima-blood boundary. The media-intima boundary is again relatively smooth in the normal vessel and often invisible or nearly so due to a sensitivity to sound interrogation angle. Also, the mechanical properties across the boundary are similar, resulting in weak echoes.

One can get an estimate of the location of the adventitia-media boundary by observing the end of the echoes from this boundary and subtracting an approximate echo pulse length, although this depends on echo strength and system gain setting. As disease develops, and the intima thickens, it may be possible to see a rougher media-intima interface, and the actual intima-blood interface, if the echoes from within the intima are not particularly strong. With significant lesions present, a close estimate of the intima-blood boundary can be made by marking the end of the echoes from this boundary and again subtracting the echo duration.

In summary, when sound travels from outside to inside of the arterial wall, only the intima-lumen boundary (boundary 3) is well defined although it may often be invisible or nearly so due to similar mechanical properties across the boundary and sensitivity to angle. With disease, it is more readily seen and inability to visualize tends to suggest absence of disease. With significant disease, the intima-blood boundary may be approximated by identifying the bright-dark transition after this echo. Similarly, the adventitia-media boundary (boundary 2) may be approximated by identifying the correct bright-dark transition.

#### 5.4.6 Effects of Arterial Geometry

##### 5.4.6.1 Transverse Cross-Section.

The transverse cross-section of a vessel segment which is nonbranching is normally considered to be nearly circular. However, the high sensitivity to interrogation angle of boundaries 3 and 4 in B-mode images can result in a high frequency of invisible boundaries when opposite sides of the artery differ only a few degrees from being parallel. For example, if the blood-intima boundary on the far wall is visualized, there is a good chance that the intima-blood boundary on the near wall will be invisible and vice versa. Rough boundaries, such as the media-adventitia boundary on the far wall (boundary 5) and the adventitia-media boundary on the near wall (boundary 2),

are relatively insensitive to these deviations from circular cross-section and are more often visualized.

#### 5.4.6.2 Longitudinal Cross-Section (Curvature)

In a similar manner, if the artery curves within the scan plane, or bends outside of the scan plane, there may be only a small segment of (smooth-weak) boundaries which satisfy the sound angle requirement at one time. Consequently, unless a segment is very straight, only a small portion of a boundary such as the far wall blood-intima boundary will be visible. The rougher boundaries are not as sensitive to curvature, and are visualized more frequently.

#### 5.4.7 Effects of Blood Flow and Respiration

Arterial geometry may be altered during both the cardiac and respiratory cycles by the regular changes in blood pressure during systole, diastole and respiration. Some interfaces may be visualized during part of the cardiac cycle and not at others, particularly smooth-straight-weak interfaces. Capturing such frames at systole or diastole must contend with these problems. Careful attention should be paid to wall motion in attempting to identify the several boundaries.

#### 5.4.8 Simple Arterial Models

An ultrasonic B-mode image of an artery differs significantly from an optical image of the same vessel. A significant amount of artifact (false or misleading information) is present in the B-mode image, and a reader must be aware of the fundamental limitations inherent in interpreting such images. In this section, several simple idealized models are discussed to help identify some of these situations. Readers should also refer to recent papers entitled, "Artifacts in Ultrasound Imaging" by Dr. F. W. Kremkau and "Intimal plus medial thickness of the arterial wall: a direct measurement with ultrasound imaging" by Dr. P. Pignoli.

In Figure 11 (Real Boundary), a sound pulse traveling from left to right and encountering a single boundary is considered. If the acoustic impedances of the two media are different, an echo arises and is received by the sending transducer. In Figure 11 (High Gain), the appearance of this single boundary on the B-mode image is illustrated when the ultrasound system gain is high. A "literal" interpretation of this B-mode image would lead one to believe that a thin "layer" (the bright region) of material was present in the path of the ultrasound beam; however, in reality only one boundary is present. The apparent thin "layer" arises because of the finite time duration of the ultrasound pulse which is launched from the transducer. The apparent thickness of this "layer" has no physical relationship to the dimensions of the boundary. The real information presented in this image is the location of the boundary on the left side of the thin "layer".

In Figure 11 (Low Gain), the appearance of this single boundary model on a B-mode image is illustrated when the ultrasound system gain is low. Note that the thin "layer" is now less thick than in Figure 11 (High Gain). The left side, i.e. the location of the boundary, of this thin "layer" is essentially at the same location, whereas the right side has moved substantially, suggesting an apparent decrease in thickness of this boundary, when in fact, the boundary has not changed. Thus gain settings do affect the ultrasound

echo duration significantly, but do not alter position of the left boundary in the B-mode image. Measurements made on the left side of a boundary are essentially gain (brightness) independent.

Figure 12 (Real Boundaries) shows a sound pulse again moving from left to right, now through two simple boundaries. With high gain setting, the B-mode image arising from each of these boundaries is shown in Figure 12 (High Gain). If the relative strength of the echoes at the two boundaries is different, the effective differences in pulse durations will make the corresponding thin "layers" appear to have different apparent thicknesses. To measure the distance between the boundaries on the B-mode image, the left side of each thin "layer" is located and the measurement of the distance is made between those two lines. As seen in Figure 12 (Low Gain), the distance between these two lines is essentially unchanged when the system gain is lowered even though the apparent thicknesses of the thin "layers" has been reduced. Consequently, separation distances between real boundaries measured from B-mode images are essentially independent of system gain.

In Figure 13 (Real Boundaries), two sets of three boundaries are shown to simulate a simple interface model of two normal "arterial walls" consisting of a relatively thick "media", a relatively thin "intima" and a homogeneous "adventitia".

With high gain, the corresponding B-mode image is shown in Figure 13 (High Gain). Note that the interfaces of the "intima" are so close that the pulse length of the ultrasound system prevents them from being resolved. The greater thickness of the dark region, i.e. "media", however, permits this region to be identified in this interface model of the left wall.

On the right wall, the distance between the "intimal" boundary and the "media-adventitia" boundary is clearly delineated, and the thickness defined by these interfaces is readily measured on this wall. When the gain is lowered, these two distances are not significantly altered as shown in Figure 13 (Low Gain).

If we add to this simple interface model a relatively homogeneous "adventitia", the boundary between the "adventitia" and "media" on the left wall is obscured by echoes arising within the "adventitia", adjacent to the "media" boundary. This is illustrated in Figure 14. When this occurs, direct measurements of the "media" thickness on the left side are no longer possible. The "intima plus media thickness" on the right side can however be measured as shown previously in Figure 13 (Low Gain).

In general, echoes arising within the adventitial tissues are relatively strong and remain bright when the system gain (brightness) is dramatically reduced.

THE SPECIFIC BOUNDARIES, LABELED BY 2, 3, 4 and 5 ON FIGURE 14 (High Gain) ARE THE ONES TO BE IDENTIFIED AND MEASURED ON EACH OF THE IMAGE FRAMES SELECTED.

Please note that while boundary 3 is actually located at the dark-to-bright (left side) transition of the echo shown, the bright-to-dark (right side) transition marked 3, permits a better determination of the near wall (intima plus media) thickness for a wide range of arterial conditions.

### 5.5 Identification of Principal Boundaries from the B-mode Images

Representative B-mode images of the carotid arteries are shown in Appendix I. The location (or estimate) of each of the four boundaries (2,3,4 and 5) within the middle 10 mm of the image is sketched in the enlarged second image of each pair. This is the segment which is read and which has the least geometric image distortion.

Beginning readers should carefully study these figures before beginning the reading process. Particular attention should be paid to the identification of these boundaries when lesions are present. Wall motion is an important tool which should be routinely used to identify the important wall boundaries. Individual image frames recorded between diastole and systole should be carefully analyzed to clearly distinguish between vein wall and artery wall, to select the frame closest to systole and to identify artifacts which are clearly not associated with the principal boundaries being read. Images having unusual features (e.g. boundaries which are difficult to identify and possible artifacts) should be discussed with the chief reader before performing the measurements. If the reader deems it necessary, he/she may review the video cassette tape after reading an image.

### 5.6 Calibration of Image Pixel Size

At the beginning of each participant study, a calibration frame is read. An example is shown in Figure 15. Frame selection is determined by a frame with the best visualized hatch marks on the lower portion of the measurement image.

### 5.7 Procedure for Reporting Alert Values

Procedures for reporting possible alert values to the Ultrasound Director at the field centers are initiated when the minimum residual lumen in the carotid artery is  $\leq 2$  mm. Identification of these possible alert values is carried out by the sonographers performing the scans at the field centers or by the readers at the Ultrasound Reading Center. When a field center sonographer suspects one or more sites on the carotid artery meet the possible alert value criterion, the back-up copy of the participant's tape is sent to the field center's Ultrasound Director for reading, in addition to the regular data transfer procedures to the Ultrasound Reading Center.

When an Ultrasound Reading Center reader measures or suspects that the distance between boundaries 3 and 4 is  $\leq 2$  mm (readings at the URC are limited to protocol sites), the chief reader is notified immediately to visually confirm the reading. The alert value variable in the database is recorded as "Yes" for storage in the ultrasound database. A FAX message is sent to the field center, identifying the participant and the site(s) in the carotid artery in which a possible alert value has been measured or is suspected. The participant's ID and the date of the Fax alert value transmission to the field center is logged for future reference.

Upon receipt of an E-mail message of a possible alert value, the procedures in the field center become identical to those followed if an alert value is suspected by the sonographer. The resolution of possible alert values is the function of the field centers; at the recommendation of the field center Ultrasound Director in accordance with local community standards, a statement documenting the possible abnormal findings of the ultrasound scan may be

included in the Summary of Results for Participants and their Physicians. Field centers keep a log of actual alert values.

#### **5.8 Placement of Crosshairs on Principal Boundaries**

A crosshair is used on each of the identifiable boundaries to mark its location at 11 specific locations as shown in Figure 16. The coordinates to these locations are stored in the central computer and used to compute dimensions of arterial lumens and wall layers. A maximum of 44 locations is recorded if all boundaries are clearly visible. In many cases, between 25 and 35 locations are the number actually marked, due to lack of sufficient information in the image.

Based upon the discussion in section 5.4, if a sonographer has made every effort to visualize the four boundaries being measured, missing data is generally (the shadowing artifact being the exception) an indication of the absence of disease within the arterial walls.

Figure 7 Geometry of B-mode Images

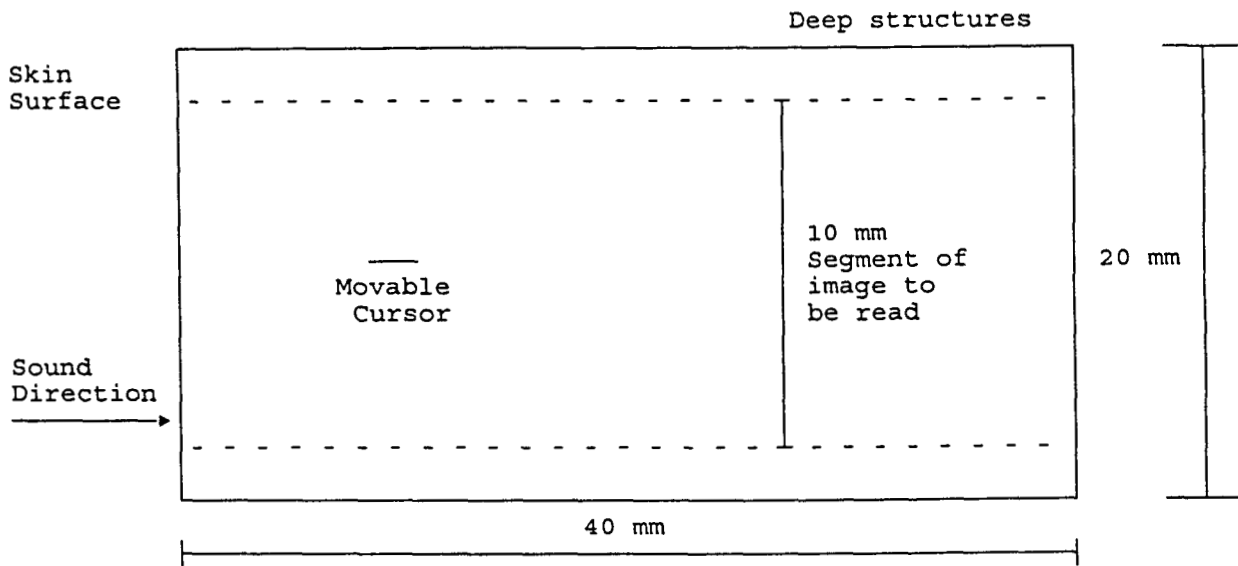




Figure 8 Diagram of the Arterial Tree

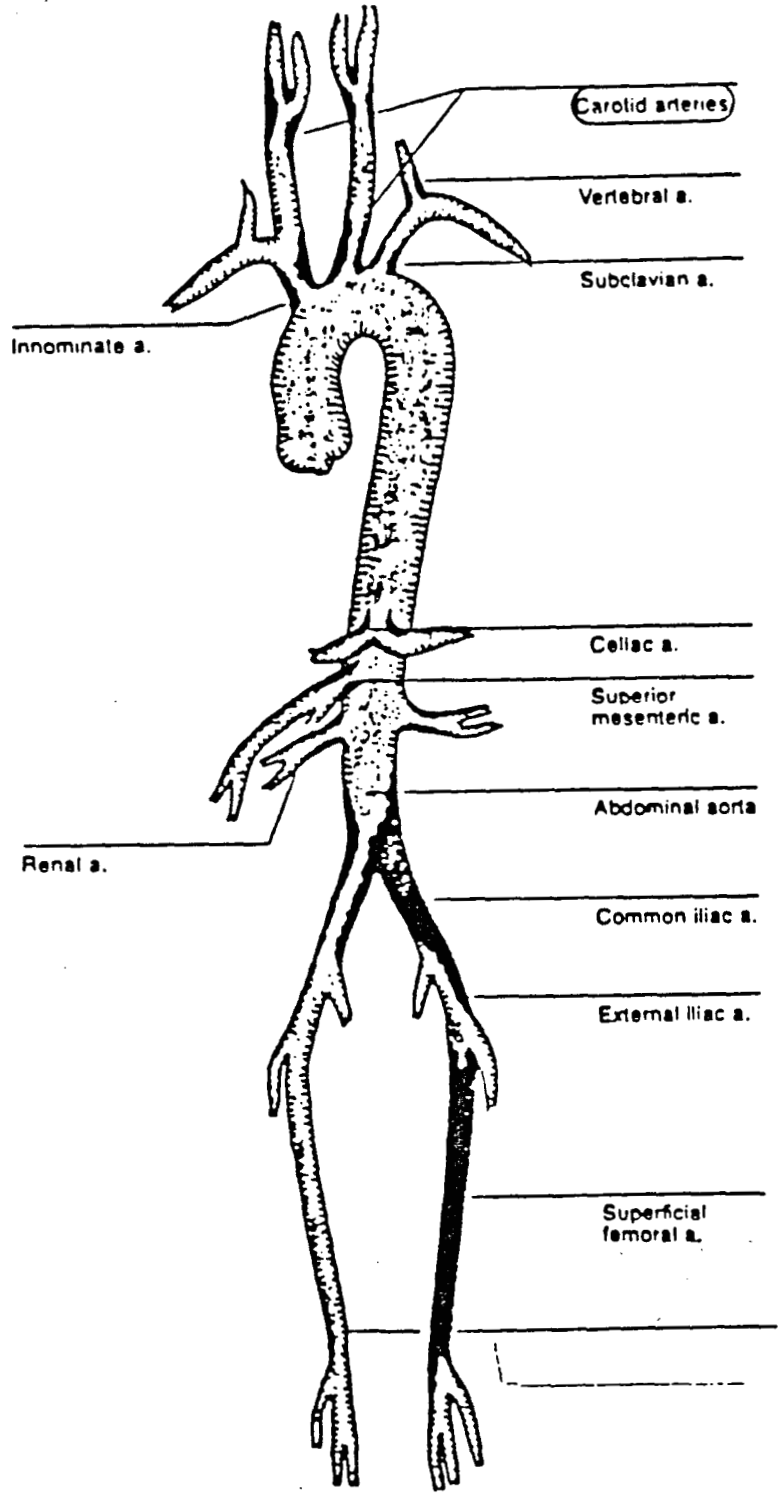


Figure 9 Simplified Diagrams of the B-mode Images to be Read

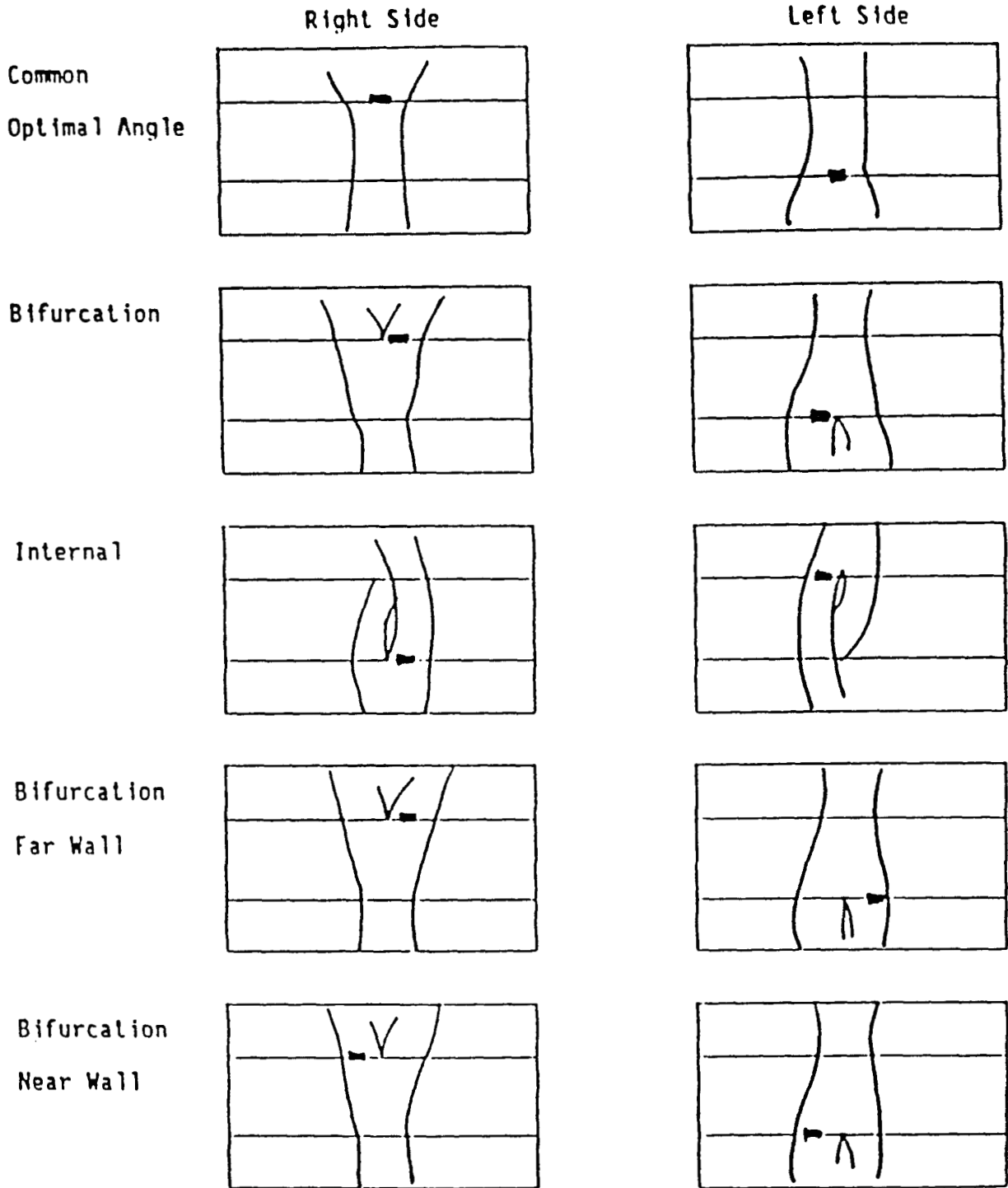


Figure 10 Diagram of the Arterial Wall Layers

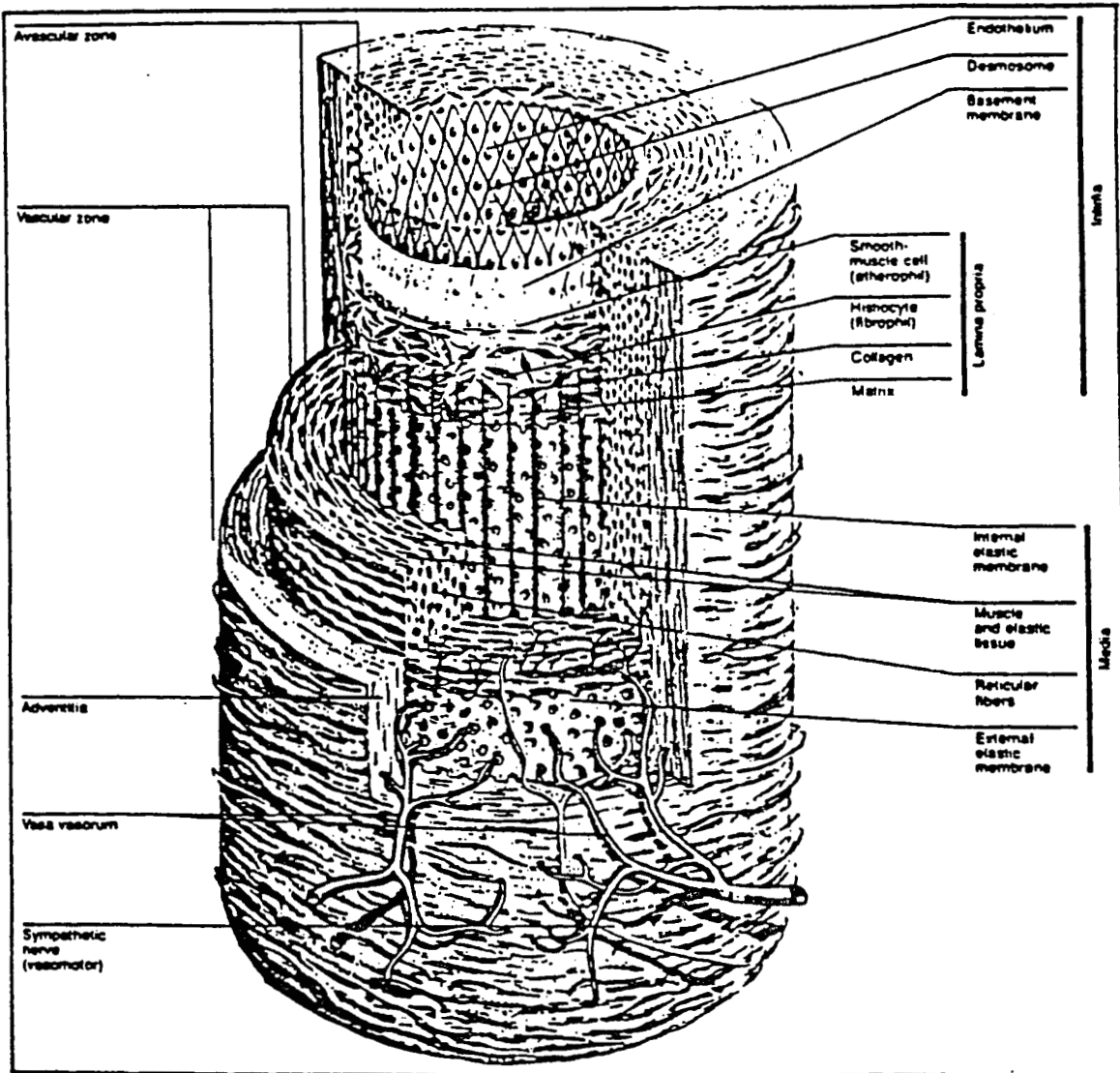


Figure 11 Idealized B-mode Image of a Single Boundary

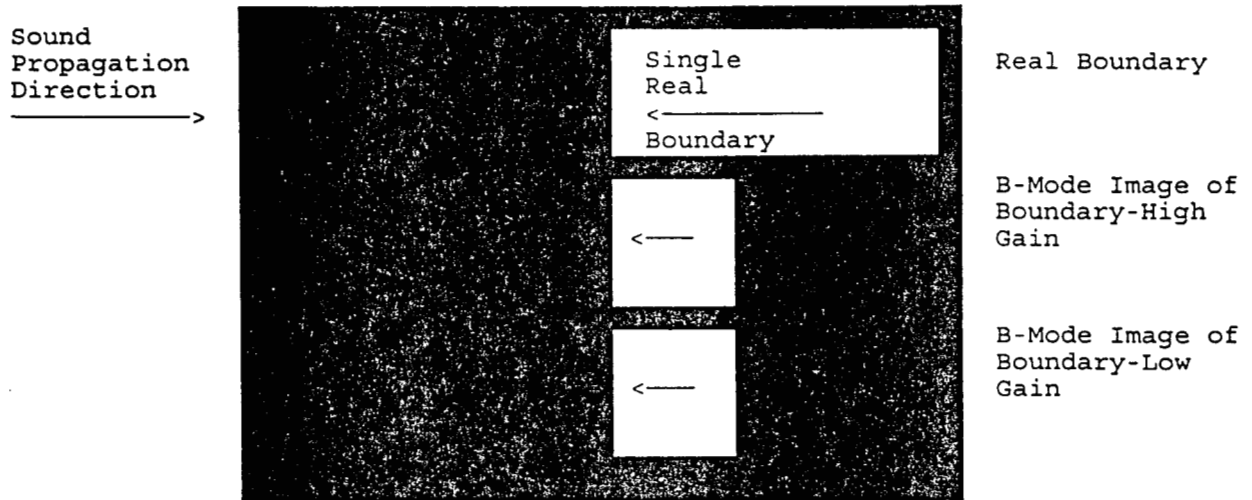


Figure 12 Idealized B-mode Image of Two Boundaries

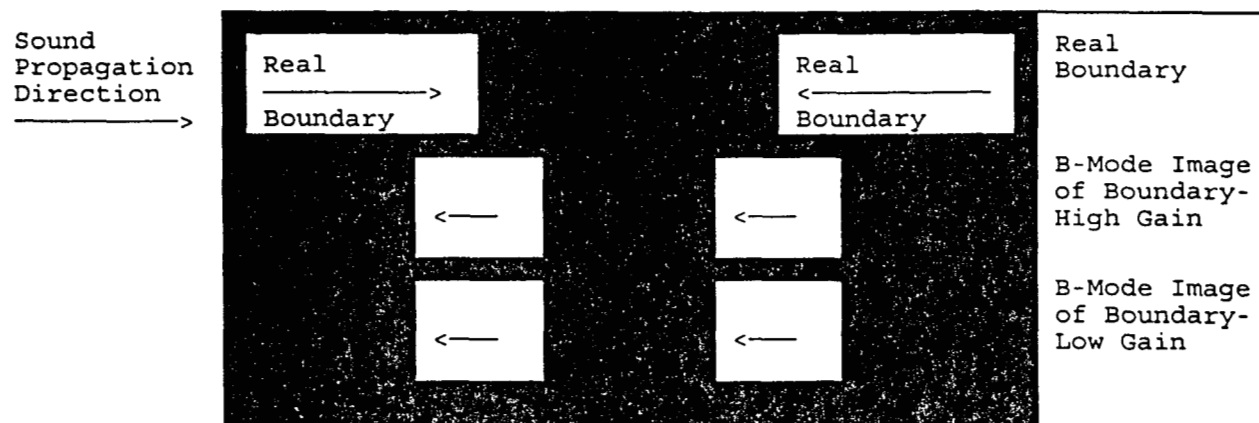


Figure 13 Idealized B-mode Image of Boundaries Simulating Arterial Walls




Figure 14 Idealized B-mode Image of Boundaries Simulating Arterial Walls




Figure 15 Biosound Calibration Frame for Determination of Image Pixel Size

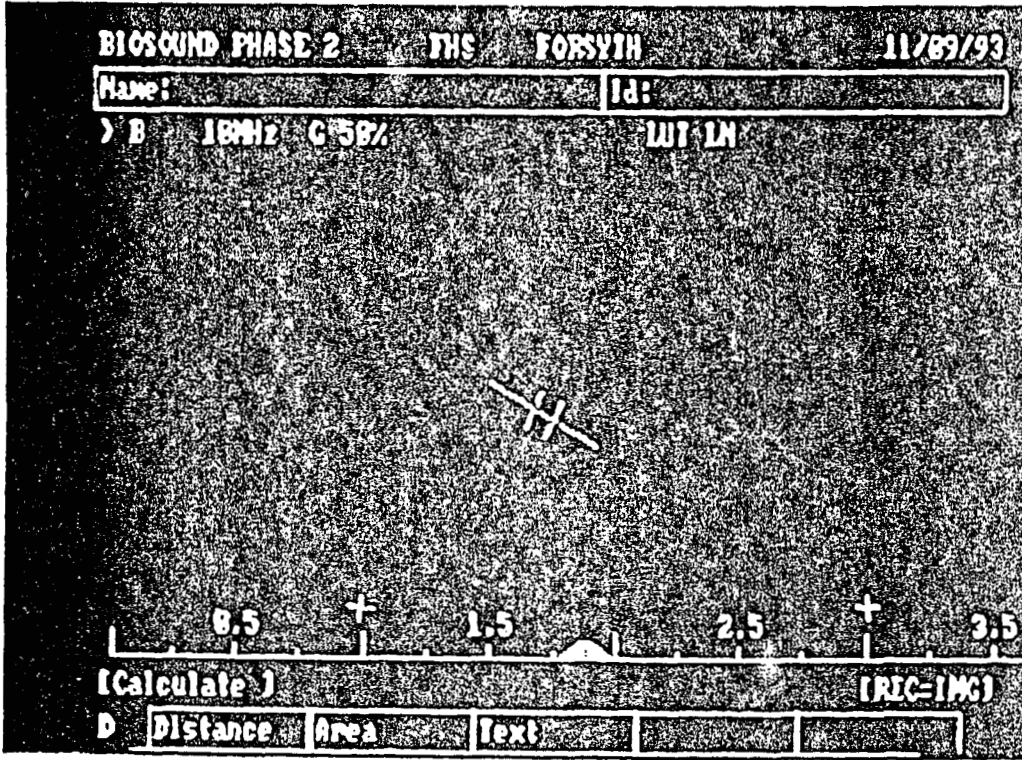





Figure 16 Place of Crosshairs on B-mode Image Boundaries



## 6. OPERATION OF THE READER STATION

### 6.1 Equipment Start-up and Login

1. IN THE FOLLOWING ORDER, turn on the sVHS, VCR, Vid/IO box, Panasonic TV monitor and personal computer. Peripheral devices should be turned on before the computer monitor to prevent a power surge to the personal computer.
2. Log on to the central computer.

### 6.2 Transfer of Participant Files from the Central Computer

The reader obtains a study code sheet, the reader transfers a participant study from the central computer to the reader station PC before beginning reading. The participant ID# is located in the upper right hand corner of the study code sheet. The file transfer procedure is on file at the Ultrasound Reading Center.

### 6.3 The Image Measurement System

At the C:> prompt type aric, and press ENTER. Follow instructions displayed on the computer screens. The instructions are color coded as follows:

- yellow - current position
- pink - sites to be read or information
- green - sites that have been read where data has been saved to the hard disk
- red - sites unavailable for measurement

#### 1st screen

Type in the data as requested by the yellow highlighted categories. Press ENTER after each data entry. Note that the participant number should be preceded by an "X" (eg. X555555) and the reader number is a 3 digit number. A leading zero is used for numbers less than 3 digits.

#### 2nd screen

In addition to the information previously entered by the reader, this screen contains the sonographer notes about the scan. Read the information. The reader should then follow the instruction at the bottom of the screen to "Insert tape and hit ENTER." Verify the cassette number with the number on the reading sheet and in the information at the top of this screen. Next, the message "Enter when ready to proceed" appears in yellow. When the VCR is in the "pause" mode, the reader presses ENTER. The Panasonic monitor is placed on "A" line.

#### 3rd screen

Reading sites are listed with the Start Code 012 highlighted in yellow. This is the site code for calibration. (If there is no Start Code 012 report the missing site to the chief reader. Do not continue reading the study until the Start Code has been added.) Follow instructions "Enter when ready to proceed."

If the frame captured is acceptable for the reading process, press **ENTER**. If the frame is not suitable for calibration, use the arrow key to highlight **NO**, and press **ENTER**. Repeat the capture process until an acceptable image is captured for reading. See Section 5.6 for acceptable frame requirements.

Press **ENTER** with **YES** highlighted when an acceptable frame is obtained. Follow the instructions to bring up the crosshair using the arrow keys and move it into position on the appropriate hatch marks. Press **ENTER** to mark each point. Switch to line B on the Panasonic monitor and put the VCR in play to visually review the scan before making measurement.

After reviewing the scan, site and frame selection can begin. See Section 5.2 and 5.6 for acceptable frame requirement for each site read.

The first site is highlighted in **yellow**. To access the toned frames for this site, use the down arrow key to highlight the second set of frame numbers under the **SITE ADDRESS** section. Press the **HOME** key to have the VCR move to this address. The first frame of this toned area will also be highlighted under the **CURRENT ADDRESS** heading. A frame-by-frame review can now be done to select 3 frames. The frames are advanced by using the right (**→**) arrow key. When an acceptable frame is found, press the **space bar** to select this frame. The selected frame is now listed as frame number one under the **SELECTED ADDRESS FRAME** heading. Continue moving frame by frame until 3 frames have been selected.

During the frame selection process the VCR is in the "pause" mode on the VCR. This mode will time-out in 5 minutes and the VCR will move into the play mode. If this happens before frame selection is complete, press the **HOME** key to take the VCR back to the current address. Continue with frame selection so frame selection can be completed.

Once three frames are selected, press **ENTER**. The VCR will capture these three frames and present them in rotating order on the Panasonic monitor for preview. Switch the Panasonic monitor to the A line to view the frames. Frame numbers are highlighted in **yellow** as they rotate under the **CAPTURED ADDRESS** heading. Choose a frame to read and press **ENTER** to end the preview.

The first captured address will be on the Panasonic monitor and highlighted in **yellow** on the computer screen. Frame selection is made by highlighting either **YES** or **NO** at the bottom of the screen with the arrow key and pressing **ENTER**. If **YES** is selected the data entry screen will appear and reading can begin on the chosen frame. If **NO** is selected the second captured frame will be presented and highlighted and so on. If **NO** is selected for all frames the selection process must be done again and three new frames captured. Note: only one frame can be selected after **YES** is entered the selection process ends and the reading process begins.

#### 4th Screen

The reading screen appears on the PC monitor. The site and the address and frame number to be read will be displayed at the top left of the screen. The X-Y coordinates for each boundary are displayed at the top right of the screen as they are ready. Boundary options and directions for operation of the reading/measurement process will be displayed at the bottom left of the screen. If none of the boundaries for a site are readable, then the reader must capture a frame and "zero out" the boundaries by pressing **CONTROL** and the

left arrow keys simultaneously. All of the boundaries will then be stored as zeros. If this is not done the data will not reflect that the site has been read.

If the reader chooses to read the boundary, he/she must use the right arrow key to highlight READ and the boundary in yellow; and, then press Ctrl + the right arrow key. If this is the first boundary read for a particular site, "Locate cursor" will appear at the bottom of the reading screen and a crosshair will appear on the Panasonic monitor. Use the arrow keys to position the crosshair on the cursor or on the cursor's horizontal plane and press ENTER. Next, the message "mark interface" will appear at the bottom of the reading screen and the boundary is ready to be read/measured.

The reader should position the crosshair at the point on the boundary to be measured by using the left and right arrow keys, and press ENTER to mark boundary. When ENTER is pressed the crosshair will move to the next pixel increment. When all possible points on the boundary have been either measured or skipped, the reading of the boundary is ended by pressing the END key. This will register the boundary measurement(s) on the reading screen in the appropriate boundary X-Y Coordinates' column and in the file to be stored later. Use the arrow keys to move to the next boundary to be measured and repeat the above procedures for reading and measuring boundaries. As the boundaries are read the X-Y coordinates will appear in the column that identifies the boundary (X2, X3, X4, X5). This identifies the points that have been read or skipped.

When measurements are made at the same y coordinate for both boundaries of a wall, a wall thickness-measurement is displayed. The maximum and average wall thicknesses are computed and displayed for evaluation of the measurement by the reader. The reader evaluates the measurement and proceeds according to screen instructions.

The Quality screen for this the preceding site appears on the PC monitor.

#### 6.4 The Database Screen

The Database screen is a list of questions concerning the frame which the reader has just read. Appropriate answers are entered with the keyboard. The last question asks if all the questions were answered correctly. If it is answered Y, these data are stored along with the coordinate data in the computer. If the last question is answered N, any information on the Database screen may be corrected. Upon completion of these questions, the program returns to screen 3. The reading process is repeated until all available sites have been read.

## 6.5 Ending the Reading Session

After all sites have been successfully read, the reading process is complete for the participant study. To end the reading, the reader is given an option to terminate the reading program.

### 6.5.1. Sending Data to the Central Computer

Computed readings are transferred to the URC central computer. The procedure for sending these completed readings is on file at the Ultrasound Reading Center.

### 6.5.2 Log Out

When reading is complete for the day, the reader logs off the central computer. This procedure is on file at the Ultrasound Reading Center.

Turn off computer, and then peripheral devices in order to prevent a power surge to the PC.

## 7. URC QUALITY CONTROL PROGRAM FOR BIOSOUND INSTRUMENTS

An ongoing quality control check of Biosound instruments is coordinated through the URC. Twice a month, at each field center, an RMI tissue mimicking phantom is scanned and the video cassette sent to the URC for evaluation. The quality control evaluation, performed on this scan by a certified reader consists of the following:

- a. Evaluation of image quality;
- b. measurement of axial resolution and axial and lateral diameter of a simulated vessel in the phantom;
- c. measurements of pulse length and focal accuracy on a set of filaments within the phantom;

This program has been established to insure that arterial images obtained from the Biosound equipment at each field center conform to uniform standards of quality, accuracy and repeatability. With a scan of identical phantoms, consistency is maintained throughout the project.

### 7.1 Instrumentation

The reader work station personal computer and monitor is utilized for evaluation of phantom scans. An oscilloscope is used to measure signal strength, and a video cassette player and monitor with audio is used to view the tape.

### 7.2 Reader

A certified reader at the Ultrasound Reading Center, familiar with the phantom protocol, performs the twice monthly quality control.

### 7.3 Phantom Scan Data Flow

Scans are read the week the videocassettes arrive at URC. Data obtained from the phantom scans are recorded by the reader on Phantom Measurements sheets (Figure 17 and 18). Data are also entered once a month on a Q & A database.

### 7.4 Phantom Scan Videocassette Flow

Phantoms are scanned at each field center on the second and fourth Wednesday of each month and when a transducer is changed and/or service work is performed. The videocassettes containing the scans are sent with the usual shipment of participant studies. Each field center maintains three cassettes for phantom scans, and these are rotated until they are full. When cassettes arrive at URC, they are logged in by the reader on phantom tape log sheets (Figure 19), in the phantom field center log book. Upon completion of evaluations, tapes which still have available space are rotated back to their respective field centers. Full cassettes remain at URC in long term storage.

### 7.5 Phantom Scan Evaluation

The Phantom scan is a transverse view of a 6 mm diameter simulated vessel. It is centered vertically as indicated by a cursor. The filaments range from 0.5 to 4.0 cm in depth and are spaced at 5 mm intervals. They appear lined up across the screen in vertical center.

### 7.5.1 Equipment

Video output from the videocassette player is directed to the computer.

### 7.5.2 Login

Each tape is logged into a Login notebook in the appropriate field center section. The tape is identified by an ID number written on the front of the video cassette and along the long edge of the video cassette case. (Figure 20).

### 7.5.3 Obtaining the Data

- a. At the C:\> prompt, type in "CPS", and press <ENTER>. Press the <F1> key until the C:\ > prompt appears again. Type in "OLDCPS" and press <ENTER>.
- b. The video cassette is inserted into the player and rewound. The tape counter is set to zero.
- c. The tape is fast forwarded to the area of the last time recorded on the Phantom Tape Logsheets. The actual start time obtained from the tape counter is recorded on the appropriate Logsheets and on the Phantom Measurements form.
- d. The tape is played through the entire scan and observed for artifact and interference, and this is noted on the Phantom Measurements form and the Phantom Tape Log. The tape stop time as indicated by the tape counter is also recorded on these forms. The reader then rewinds the tape to the start time.
- e. The reader pushes PLAY, and the scan begins, the top portion of the Phantom Measurements form is filled out using the information displayed on the monitor in the heading above the scan.
  - the field center and sonographer ID numbers
  - the Phantom serial number
  - the Transducer serial number
  - the date of the scan

### 7.5.4 Axial Resolution Measurements

- a. When an appropriate image is obtained and noted verbally on the audio portion of the videotape by the sonographer, the reader presses <ENTER> to capture the image.
- b. The main menu is displayed on the computer monitor. The reader presses the arrow key until MEASURE is highlighted, and ENTER is pressed.
- c. An arrow key is pressed until POINT is highlighted, and then ENTER is pressed. A crosshair appears on the screen which is used to measure the simulated vessel.
- d. The crosshair is moved with the arrow keys to the level of the cursor and the Y coordinate is recorded on the Phantom Measurements form. The pixel coordinates are at the top right of the computer screen.
- e. Staying on the same Y coordinate, the reader moves the crosshair to the front of the near wall echo, then to the back of the near wall echo. The X coordinates are recorded for both on the Phantom Measurements form. The axial resolution for the near wall is calculated by subtracting, and these calculations are recorded on the same form.
- f. This procedure is repeated for the far wall staying on the same Y coordinate as the cursor.

#### 7.5.5 Axial Diameter Measurement

The axial diameter is found by subtracting the near front coordinate from the far front coordinate.

#### 7.5.6 Lateral Diameter Measurement

The lateral diameter is measured through the center of the vessel. To find the X coordinate of the center of the vessel, add one half of the axial diameter (it may be necessary to move up one number, 85 to 86) to the near wall front coordinate.

- a. With the crosshair on this center X coordinate, the crosshair is moved along the Y axis to the dark-to-light transition at the top of the vessel, and this top boundary is recorded on the Phantom Measurements form. The reader remains on the same X axis coordinate and repeats this step for the bottom boundary of the vessel.
- b. The bottom boundary is subtracted from the top boundary, and the result is the Lateral Diameter, which is recorded on the Phantom Measurements form.

#### 7.5.7 Ratios

Ratios are calculated by dividing the lateral diameter by the axial diameter and the axial diameter by the lateral diameter. These calculations are recorded on the Phantom Measurements form. Lateral to axial diameter ratios should be .90 or above.

#### 7.5.8 Filament Measurements

The following steps are under consideration:

- a. The F1 key on the computer is pressed until the Main Menu appears. Use the arrow keys to highlight ACQUIRE. Press ENTER. Highlight CAMERA and press ENTER.
- b. The filament section of the scan is located on the videotape. The VCR is put into PLAY. When a suitable filament image appears, as indicated by sonographer comments in the audio portion of the videotape, press <ENTER> to capture this image.
- c. The main menu appears. The reader moves to MEASURE with the arrow keys, and presses ENTER. The arrow key is pushed until POINT is highlighted. Press ENTER. A crosshair appears on the computer screen.
- d. The crosshair is moved with the arrow keys to the level of the cursor and the Y axis coordinate is recorded.
- e. The front and back side of each reflection at cursor level is measured on the X axis, with the measurement recorded on the measurement sheet.
- f. The distances from filament to filament are calculated and compared to the manufacturer's specifications.
- g. The lateral length of the one or two filaments nearest the focus delta are also measured by moving the crosshair to the top and bottom of each filament. Data is entered on the measurement sheet. The reflection with the least lateral width with the focus switch of the transducer set to "far" represents the filament in the best focus.



## 7.6 Phantom Signal Strength Measurements

Signal strength measurements are done on each phantom tape received at Ultrasound Reading Center.

### 7.6.1 Equipment

The oscilloscope is turned on a few minutes to allow for warmup. The AC-GND-DC oscilloscope switch is set to GND using the vertical position knob to set the baseline. The AC-GND-DC knob is switched to DC.

Output from the videocassette player is directed to the oscilloscope with termination at the in-line monitor. The video tape is rewound to the beginning of the scan, and it is stopped when the simulated vessel image is toned. The videocassette player is placed in PAUSE.

### 7.6.2 Measuring the Simulated Vessel with the Oscilloscope

The following steps are done using the oscilloscope:

- a. The A Intensity is pressed under HORIZONTAL DISPLAY on the oscilloscope.
- b. Using the DELAY TIME position knob, the reader moves toward the center of the screen to the cursor area.
- c. B DLYD is pressed. A series of peaks appear on screen.
- d. The reader measures and records the peak voltages for the near wall, cursor and far wall on the Phantom Measurements Sheet. Measurements are now complete. The AC-GND-DC switch is switched to GND. The tape player is stopped, and the tape is rewound and placed in its case.

### 7.6.3 Ending the Phantom Measurements

- a. The oscilloscope is turned off, the cabling disconnected and the reader station is restored to its normal operating setup.
- b. The chief reader is informed of any abnormalities.
- c. If unused tape is left on any video, it is sent back to the respective field center. Full tapes are kept at the URC in long term storage.

Figure 17 Phantom Measurement Sheet

PHANTOM MEASUREMENTS  
RMI 414B Phantom  
(0.5 dB Attenuating Material)

Field Center \_\_\_\_\_ Scan Date \_\_\_\_\_  
Phantom Serial # \_\_\_\_\_ Read Date \_\_\_\_\_  
Transducer Serial # \_\_\_\_\_  
Sonographer ID # \_\_\_\_\_ Cassette # - - - -

Reader \_\_\_\_\_ : \_\_\_\_\_ - \_\_\_\_\_ : \_\_\_\_\_  
.....

MEASURES OF AXIAL RESOLUTION

Y-coordinate of Center of Simulated Vessel \_\_\_\_\_  
(indicated by placement of cursor)

X-coordinate (at level or cursor) or NEAR WALL Front \_\_\_\_\_  
Back \_\_\_\_\_  
.....

Axial Resolution (difference) NEAR WALL \_\_\_\_\_

X-coordinate (at level of cursor) of FAR WALL Front \_\_\_\_\_  
Back \_\_\_\_\_  
.....

Axial Resolution (difference) FAR WALL \_\_\_\_\_  
.....

AXIAL DIAMETER FAR Front \_\_\_\_\_  
NEAR Front \_\_\_\_\_  
.....  
DIAMETER \_\_\_\_\_

LATERAL DIAMETER

X-coordinate of Center of Vessel  
From above: Near Wall Front + 1/2 (Axial Diameter)  
\_\_\_\_\_ + 1/2 ( \_\_\_\_\_ ) = \_\_\_\_\_

Top Boundary \_\_\_\_\_  
Bottom Boundary \_\_\_\_\_  
.....  
Lateral Diameter \_\_\_\_\_

RATIOS

Lateral Diameter / Axial Diameter = \_\_\_\_\_  
Axial Diameter / Lateral Diameter = \_\_\_\_\_

Observations: \_\_\_\_\_  
\_\_\_\_\_  
\_\_\_\_\_

Figure 18 Phantom Measurement - Arterial Signal Strengths

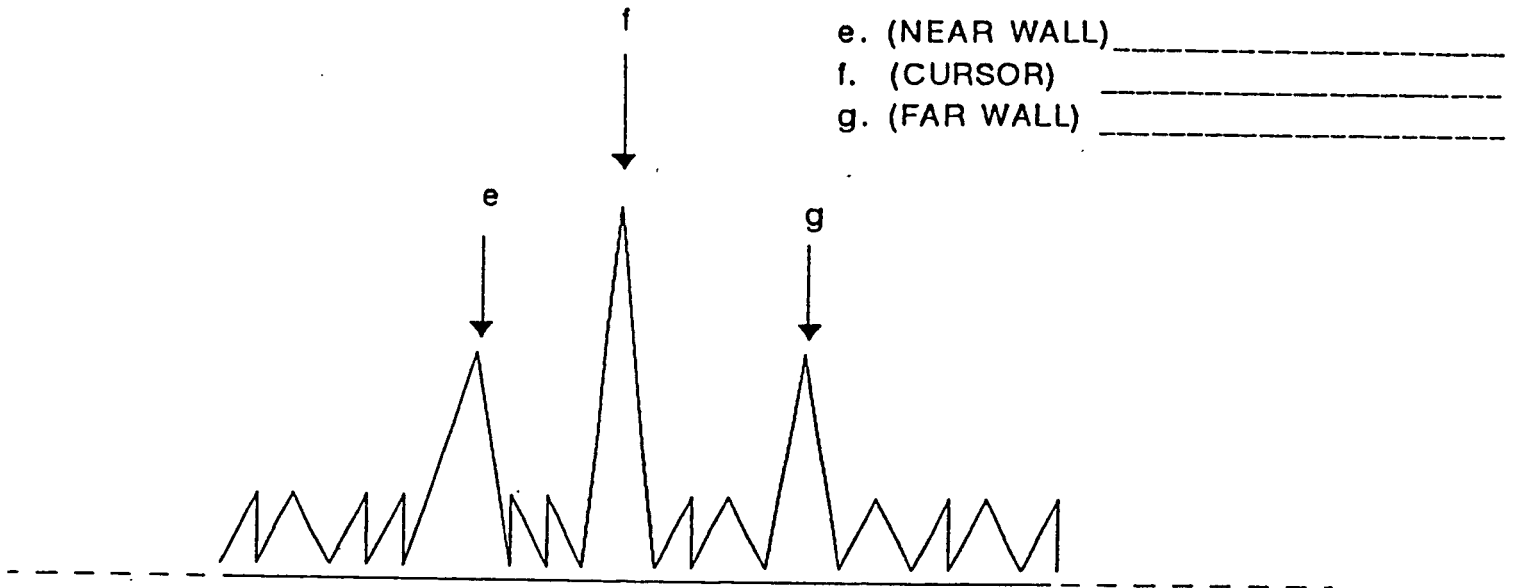


Figure 19 Phantom Log Sheet

Phantom Tape Log

Field Center \_\_\_\_\_

Tape # - - - -

Date	Time	Comments
_____	____:____ - ____:____	_____
_____	____:____ - ____:____	_____
_____	____:____ - ____:____	_____
_____	____:____ - ____:____	_____
_____	____:____ - ____:____	_____
_____	____:____ - ____:____	_____
_____	____:____ - ____:____	_____
_____	____:____ - ____:____	_____
_____	____:____ - ____:____	_____
_____	____:____ - ____:____	_____
_____	____:____ - ____:____	_____
_____	____:____ - ____:____	_____
_____	____:____ - ____:____	_____
_____	____:____ - ____:____	_____
_____	____:____ - ____:____	_____
_____	____:____ - ____:____	_____
_____	____:____ - ____:____	_____
_____	____:____ - ____:____	_____
_____	____:____ - ____:____	_____



## 8. QUALITY ASSURANCE PROGRAM

### 8.1 Introduction

In every population there is a certain amount of variability. Put in another way, a measurable variable in every normal population varies around some mean. For example, the variable that is being studied in the ultrasound portion of the study is the arterial wall thickness of the members of the population as it ages.

Likewise, in every process there is a certain degree of variability. In both equipment and in experimental methods, this variability is called the precision of the method. The processes being used in the ultrasound portion of the study include ultrasonographic scanning and the measurement of the arterial walls recorded on these scans. The combined variability inherent in these measurement processes has been determined at the outset of this study to be accurate to within two pixels, or approximately  $\pm 0.134$  mm. Said in another way, the variability of the measurement due to experimental error is plus or minus two pixels. Any variability beyond that which can be ascribed to this experimental error is assumed to be caused by a change in the population.

The URC must assure that the changes in measurements taken over the six years of Visit03-04 of this study, within the tolerances described by the study methods, are due to changes in the population as it ages, and not due to changes in the imaging process. It is vital to use a tool to rapidly discover, and reduce or eliminate any changes in the measurement process which would not be directly attributable to the population, but due to changes in the overall evaluation.

This cohort has been selected to reflect the population at large. The study design calls for participants to visit the field centers and be scanned by sonographers in a random order. Ultrasound readers are assigned to take measurement of the imaged arterial walls in a random order. Because of this randomization, it is possible to effectively employ the principles of statistical process control to continuously monitor the consistency of the scanning and reading process.

#### 8.1.1 Summary of Plan

The quality assurance program will be a program of continuous improvement for all aspects of the ultrasound evaluation process including sonographer, reader and equipment. The program is described below:

- a. Identify process variability.
- b. Identify most probable causes of variability.
- c. Determine the causes of variability in order of impact on process consistency.
- d. Develop and implement plans to reduce or eliminate the causes of variability in order of impact on process consistency, keeping in mind the ease to correct the defect, the cost to correct the defect, the impact of the class of defect on the study.
- e. Continue to monitor process for changes.

## 8.2 Process Control Charts

Process control charts are an integral part of the quality assurance program. The purpose of these control charts is to monitor the consistency of the equipment, sonography and the reading processes, and give feedback to those responsible for running these processes on a timely basis. Process control charts assume that the value being measured is normally distributed around a mean value, or process average. These charts identify changes in process consistency and give insight into probable causes of a change in variability. In this study, they can also be used to verify possible alert values, lesions and to identify participants who exhibit exceptionally thickened arterial walls.

### 8.2.1 Description of Process Control Charts

Process control charts are pairs of interrelated charts which track a process by charting the value of a variable over time. One chart plots the data points themselves. The other chart tracks the relationship of the individual data points taken at one period in time to the average of those points, as well as the relationship of the data from that time period to the next time sampling of the process. On both of these charts a calculated process average and the variability of the total process, based on the sample data is plotted. The calculated process average is represented as a central line. The expected process variability is represented on the chart as broken horizontal lines, bracketing the process average. From these two charts, the process variability can be monitored. Examples of these charts are presented later in this document. Any changes in the process are immediately apparent.

### 8.2.2 Method of Data Analysis - Hardware and Software

Data analysis will be accomplished through use of the Statistical Analysis System (SAS) software, version 6, available from the SAS Institute, Cary N.C. This software will be operating on the IBM 6000 computer in a multi-user network environment. The software package which will be utilized to produce the process control charts is the SQC product of SAS. In addition to being able to produce these process control charts rapidly and efficiently, the SQC package can run a series of tests for variability which increase the sensitivity of the charts. These tests for process inconsistency include tests for the following:

- a. Non-randomness of data;
- b. a consecutive sequence of data points either above or below the value for the process average;
- c. a consecutive sequence of data points alternating above and below the value for the process average;
- d. an indication of an upward or downward trend in the process average;
- e. an indication of a shift in the process average;
- f. an indication of an unexpected increase in process variability;
- g. indications of an unexpected decrease in process variability.

Process control charts will be developed from the virgin database at the Ultrasound Reading Center, as well as data developed specifically for the URC quality assurance program. Such special data includes reader and sonographer training data, data developed by using the arterial mimicking phantom, inter- and intra- reader comparison readings, sonographer scan tape reviews, etc.

### 8.2.3 Examples of Data to be Evaluated by This Technique

Examples of data which can be monitored in this fashion include, but are not limited to, the number of visualized points read in a study, the number of paired points visualized in one site angle, or average arterial wall thickness. A paired point is defined as corresponding points on the intima-blood interface and the media adventitia interface. These points can be tracked by reader, by sonographer, by field center and by any number of combinations of the above, charted against read date or against scan date. The number of points or paired points can also be examined, for example, as a function of time spent reading a study. Inter- and intra-reader studies will be evaluated as a measure of reading process consistency. The condition of the reading stations can be evaluated with this process, by plotting calibration factors per reading station over time. Results of routine scans of the artery-mimicking phantom by the field centers will also be monitored in this fashion to check equipment consistency.

It is important to point out that not all of the outlying points are caused by errors. Some of the outlying data points indicate individual participants whose wall thicknesses vary greatly the general population. Some of the outliers in the mean chart were due to participants with exceptionally thick or thin arterial walls. Some large standard deviations are due to focal lesion. Being aware of all the special causes of variability in the ultrasound reading process is critical to using these charts effectively.

Probable causes of changes in variability which we will monitor include, but are not limited, to the following:

- a. unusual participant anatomy
- b. exceptionally thin walls
- c. exceptionally thickened walls
- d. lesions
- e. other pathology
- f. reading equipment drift or loss of calibration
- g. sonography equipment drift or loss of calibration
- h. changes in equipment
- i. changes in reading technique
- j. changes in sonography technique
- k. frame selection by the reader

### 8.3 Special Studies

In order to monitor the effectiveness of the ultrasound data gathering program, special studies will be performed on a routine basis. One study involves having all ultrasound readers read one study per month, in order to evaluate the degree of consistency in measurements and frame selection among readers.

In addition to the process control charts, summary quality assurance reports will be produced on a monthly basis for the benefit of readers. These summaries will be made available to the readers and their chief readers, in order to monitor both equipment integrity and reader technique.



#### 8.4 Frequency

Quality Assurance (QA) summary reports will be produced on a routine basis. Reports evaluating reader performance will be produced based on read date. Reports evaluating reading equipment performance will be produced based on read date. Other internal QA reports will be produced as indicated by the process average. Inter- and intra-reader studies will be conducted routinely.

#### Handling Results/Taking Corrective Actions:

The quality of the readings of the ultrasound reading process will be managed by the control of the variability of the processes involved. Statistical techniques and concepts are presently the best methods available to describe, understand, study, control and eliminate variations. Statistical tools alone will not cause improvement in consistency of the reading process, they merely transmit information. It is the responsibility of the project manager and chief reader at the ultrasound reading center (URC) to see that quality assurance data is received and understood. It is they who are responsible for responding to the variations in a timely and appropriate basis, and for transmitting instructions to the appropriate study personnel to effect process improvement.

#### 8.5 QA reports

Quality assurance reports consist of internally distributed and externally distributed reports. These reports provide details regarding the performance of the sonographers and the readers, as well as that of associated equipment and associated processes.

#### 8.6 Readers

The mean wall thickness by reader will be calculated on a routine basis. Any single average wall thickness which deviates from this mean by greater than three standard deviations from the mean of the process average, as found by the process control charts, will be investigated. Smaller drifts, or any other evidence of non-randomized patterns, will be investigated and, where appropriate, suggestions for improving reading consistency will be made. Difficult studies and studies with exceptionally thick walls will be identified and reviewed. All readers will review a "Stump of the Month" study. This study will be one which proved particularly difficult to read and the ensuing discussions will provide insights for all the readers as to how to best interpret particularly difficult images.

In addition, a report on the quantity of data per study will be generated. This report is similar to the sonographer report on the percentage of studies with paired points along an arterial wall boundary. In addition to monitoring the ability of the sonographers and readers to image and measure arterial walls, this report will provide a measure of the condition of the ultrasound equipment at the field centers.

#### 8.7 Reports to the Quality Control Committee

Excerpts from the sonographer and reader reports will be sent to the Quality Control Committee. The quality control reports consist of study-wide and Field Center averages. Specific data on each sonographer and reader will be kept at the Reading Center. This action preserves the communication link

between the Reading Center and the sonographers and the readers. Problems can be discussed and resolved individually, as a part of continuing reader and sonographer education. This program will also help assure the consistency of method between field centers, assist in a program of continuous improvement.

**APPENDIX I: EXERCISES FOR READING B-MODE IMAGES**

Exercise 1 Right Common Carotid: Figures 21 and 22

Site: Right Common Carotid Artery

Anterior Wall Depth:  $X = 1.2\text{cm}$

Posterior Wall Depth:  $X = 2.2\text{cm}$

Cursor: The cursor is correctly placed at  $y = +0.3\text{cm}$ . This is the origin of the bulb.

Anatomical Landmark: The origin of the bulb is clearly visible at  $y = +0.3\text{cm}$ . This is the correct vertical placement of the image since it positions the area of measurement in the vertical center of the screen.

Posterior Wall: B4 is clearly visible from  $y = -0.3\text{cm}$  to  $y = +0.1\text{cm}$  and then again at  $y = +0.2\text{cm}$ . This interface is fairly distinct and continuous except for the gap which appears between  $y = +0.1\text{cm}$  and  $y = +0.2\text{cm}$ . B5 is also fairly distinct and continuous and is identified with relative confidence from  $y = -0.8\text{cm}$  to  $y = +0.3\text{cm}$ . Although there are some diffuse echoes immediately to the left of B5, a "dark" to bright transition can be seen and indicates the location of B5. These diffuse echoes also indicate the presence of non-homogeneous tissue located within the media.

Anterior Wall: B3 is visible in the range of  $y = -0.4\text{cm}$  to  $y = +0.3\text{cm}$ . Although it is not as smooth and distinct as B4, it can be identified with a fair amount of confidence. The bright to dark transition characteristic of B2 is clearly visible from  $y = -0.6\text{cm}$  to  $y = +0.3\text{cm}$  and B2 can be easily identified in this range.

Significant Artifact: There is an apparent gap in B4 located at approximately  $y = +0.3\text{cm}$ . This does not represent discontinuity of the interface but is an artifact which may be caused by a number of phenomena. For example the characteristics of this image suggests that the gap may be due to mild shadowing arising from strong reflectors or scatterers located on the anterior wall.

A - 2

Figure 21 B-mode Image of Right Common Carotid





Figure 22 B-mode Image of Right Common Carotid: Detail of B-mode Image



Exercise 2 Right Common Carotid: Figures 23 and 24

Site: Right Common Carotid Artery

Anterior Wall Depth: X = 1.4cm

Posterior Wall Depth: X = 2.7cm

Cursor: The cursor is correctly positioned at y = +0.4cm.

Anatomical Landmark: The origin of the bulb is visible in this image at the location of the cursor on the posterior wall. (The origin of the bulb can not be seen as well on the anterior wall.) The origin of the bulb is properly positioned so that the common carotid is in the middle third of the screen.

Posterior Wall: B5 is clearly visible from y = -1.0cm to y = +0.3cm. The thin, dark band to the left of B5 provides for a smooth, distinct interface, and measurements of this boundary can be made with relative confidence. B4 is also easily identified from y = -1.0cm to y = +0.3cm. This boundary is distinct and continuous, and measurements of B4 may confidently be made. In between B4 and B5 there appears to be some non-homogeneous structure which is producing echoes in this area. These echoes which appear within the media (which is most often echo-free) suggests that the instrument gain may have been relatively high. Another possibility is that the intima is beginning to thicken.

Anterior Wall: B2 is clearly visible from y = -1.0cm to y = +1.0cm, the entire length of the artery. This is a very good interface since rarely will a boundary be so clear and continuous. The absence of a dark band to the right of B2 makes it difficult to make confident measurements of B3. However, by turning down the monitor brightness B3 may be identified in the range from y = -1.0cm to y = -0.1cm. The most confident area of measurement would be at y = -0.2cm where B3 appears the brightest. The diffuse echoes which appear within the media in the lower half of the image are similar to those in the posterior wall media and may be explained in a like manner (for explanation see Posterior Wall).

Significant Artifact: B3 only appears in the lower half of the image which might suggest that there is no intima-lumen interface in the region above y = -0.1cm. B3 is probably in that portion of the artery even though it doesn't appear on the image. The "missing" interface may be the result of a slight artery curvature which would cause echoes to be bounced off the boundary in many different directions and missed by the signal receiving transducer.

Figure 23 B-mode Image of Right Common Carotid Artery





Figure 24 B-mode Image of Right Common Carotid: Detail of B-mode Image





Exercise 3 Right Common Carotid: Figures 25 and 26

Site: Right Common Carotid Artery

Anterior Wall Depth: X = 1.0cm

Posterior Wall Depth: X = 2.2cm

Anatomical Landmark: The origin of the bulb is not easily identified on the image. It should have been placed adjacent to the cursor at  $y = +0.5\text{cm}$ .

Posterior Wall: Lesion appears to be present. B4 is clearly identifiable over  $y = -0.5\text{cm}$  to  $y = +0.5\text{cm}$ . The lesion occupying the region to the right of B4 contains much speckle texture. B5 is preceded by a dark band from  $y = -0.2\text{cm}$  to  $y = +0.5\text{cm}$  and readily identified over this range. Reduction in brightness may help in identifying a more distinct dark to bright transition characteristic of B5.

Anterior Wall: B3 is not readily identifiable, probably due to improper alignment of the anterior wall with the ultrasound beam. B2 is fairly clear and should be marked with reduced brightness on the monitor. The structures appearing within the lumen are discussed below.

Significant Artifacts: The diffuse echoes appearing within the lumen to the right of B2 may be reflections from the lateral walls due to misalignment of the ultrasound or significant disease as suggested by the lesion on the posterior wall. Careful viewing of adjacent frames in the cardiac cycle is necessary to confirm an interpretation.

Figure 25 B-mode Image of Right Common Carotid

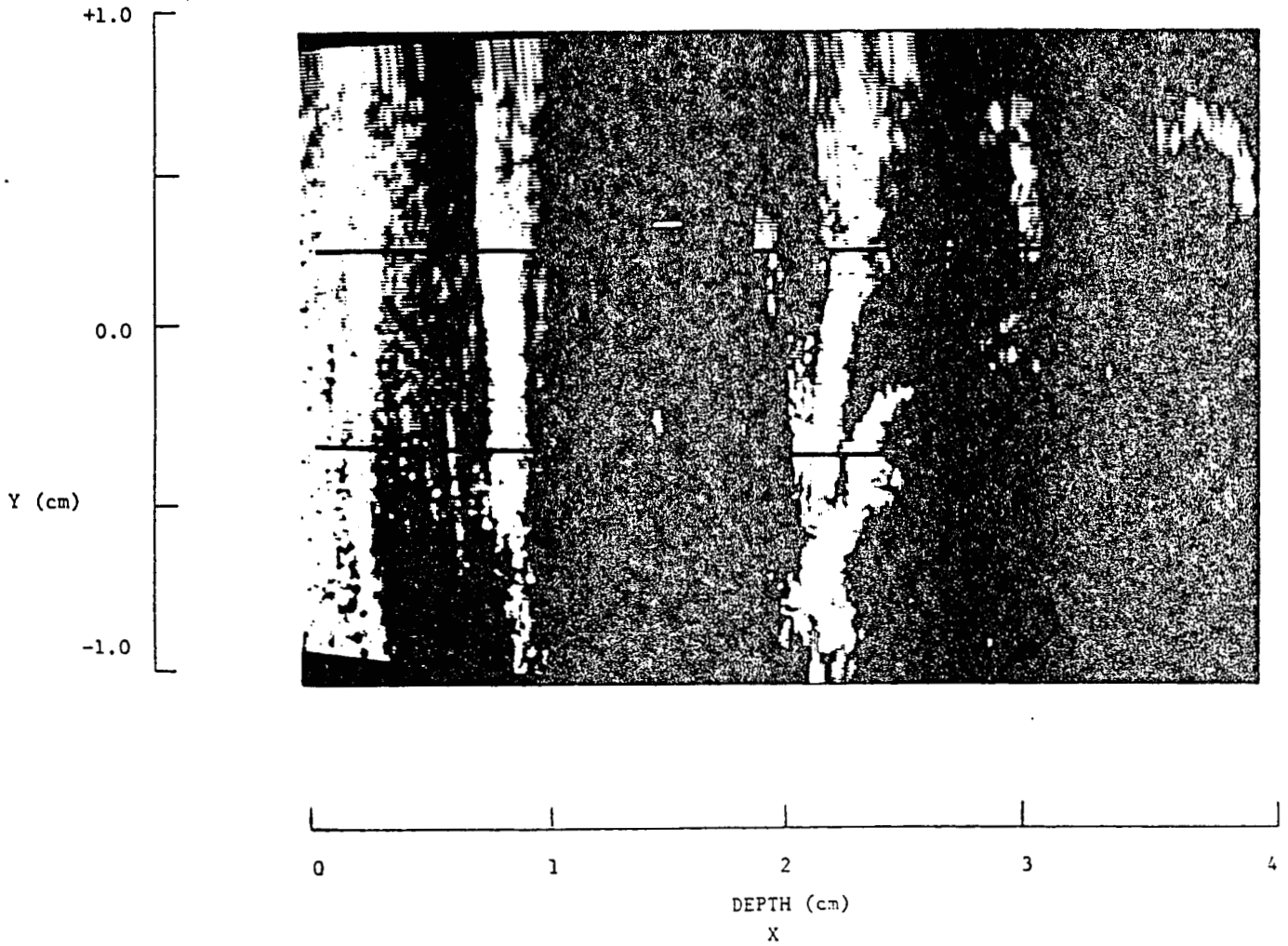



Figure 26 B-mode Image of Right Common Carotid: Detail of B-mode Image



Exercise 4 Right Common Carotid: Figures 27 and 28

Site: Right Common Carotid Artery

Anterior Wall Depth: X = 1.5cm

Posterior Wall Depth: X = 2.8cm

Cursor: In this image the cursor is placed almost in the vertical center of the screen at X = 1.2cm. This is an incorrect placement. The cursor should be placed at the origin of the bulb which appears to be located at y = +0.3cm.

Anatomical Landmark: The origin of the bulb is visible and is located at approximately y = +0.3cm. This is an ideal vertical placement as it positions the area of measurement in the middle third of the screen.

Posterior Wall: B4 is identifiable from y = -0.1cm to y = +0.2cm and is fairly smooth and continuous except for the gap which is present in the middle third of the screen. B5 is not quite as smooth and distinct as B4 but can still be identified with relative confidence from y = -0.7cm to y = +0.3cm. Turning down monitor brightness can help in identifying a more distinct dark to bright transition characteristic of B5.

Anterior Wall: The anterior wall is not very clear, and the measurements taken there will not have a high quality rating. Because of the diffuse patches of echoes preceding B3 there is no dark, echo-free band, and identification of B3 and B2 is difficult. Nevertheless, B3 may be identified in two regions along the anterior wall from y = -1.0cm to y = -0.3cm and from y = +0.2cm to y = +0.4cm. There is a slightly visible bright to "dark" transition in the area of B2, thus this boundary may be identified from y = -1.0cm to y = +0.7cm. Lowering of the monitor brightness may eliminate a significant amount of the diffuse echoes between B2 and B3 and make identification of these interfaces easier.

Significant Artifact: Speckle adds apparent texture to both walls, particularly the posterior wall in the area of B5. The "gap" in B4 is either a result of transducer misalignment or shadowing from strong reflectors on the anterior wall. The echoes in the region between B2 and B3 seem to indicate heterogeneous tissue in the media, however, the echoes are probably the result of ultrasound beam-arterial wall misalignment.

Figure 27 B-mode Image of Right Common Carotid


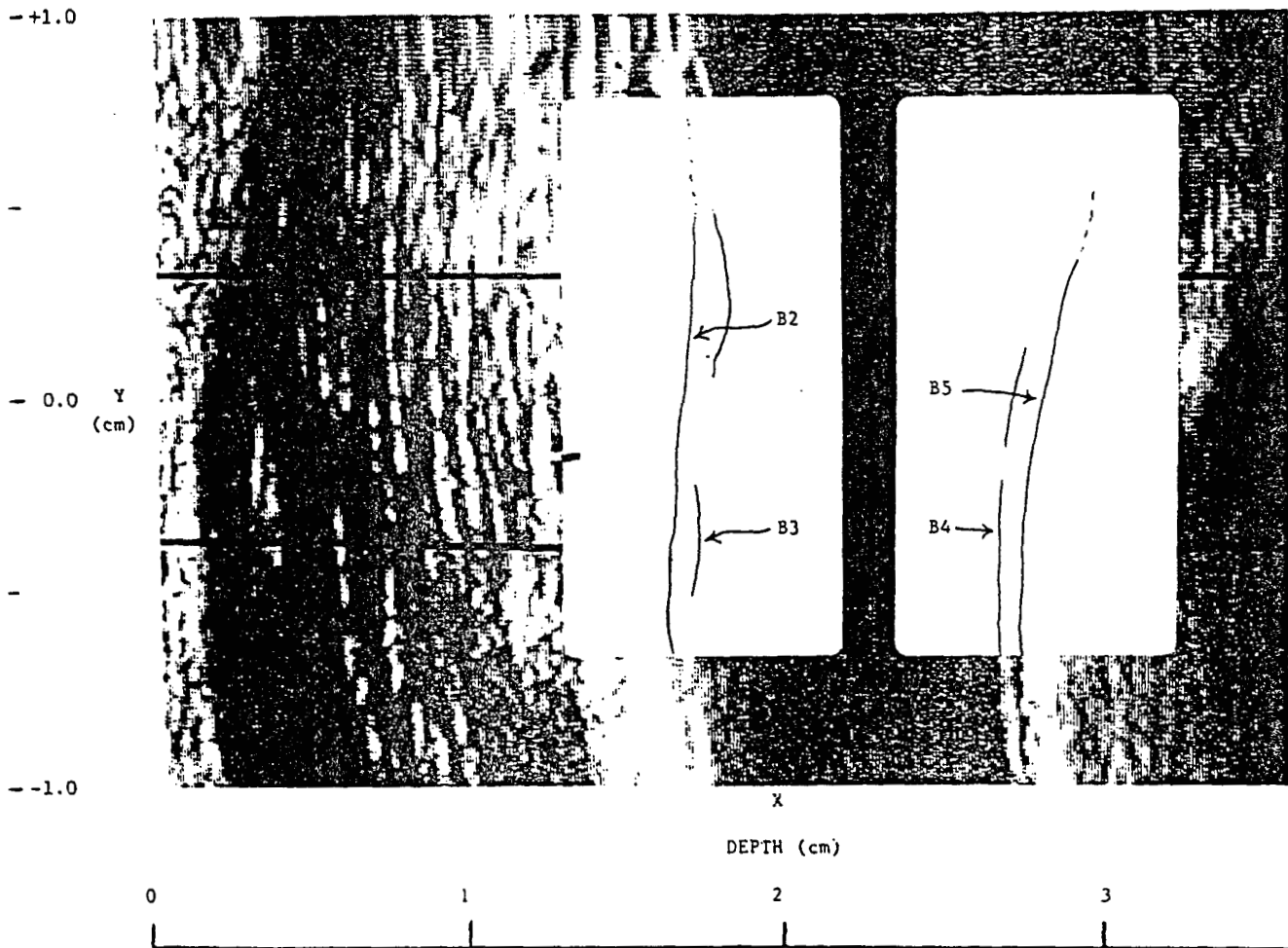


Figure 28 B-mode Image of Right Common Carotid: Detail of B-mode Image



## Exercise 5 Right Common Carotid: Figures 29 and 30

Site: Right Common Carotid Artery

Anterior Wall Depth: X = 2.0cm

Posterior Wall Depth: X = 2.9cm

Cursor: Improperly placed. It should be located at the origin of the bulb located at  $y = +0.5\text{cm}$ .

Anatomical Landmark: The origin of the bulb is located at  $y = +0.5\text{cm}$ . This is the proper vertical screen placement.

Posterior Wall: B4 can be easily identified from  $y = -0.5\text{cm}$  to  $y = 0.0\text{cm}$ . There is a smooth, distinct dark to bright transition in these ranges. In the interval from  $y = 0.0\text{cm}$  to  $y = +0.4\text{cm}$  the dark to bright transition is not as distinct. In this range B4 appears to have a few gaps in it; however, measurements could still be made with a fair confidence. Along the interval  $y = -0.2\text{cm}$  to  $y = +0.4\text{cm}$ , B5 is easily identified by the continuous dark band following B4 and the distinct dark to bright transition.

Anterior Wall: B3 can be identified from  $y = -0.5\text{cm}$  to  $y = 0.0\text{cm}$ . Along this interval, there are diffuse bright patches within the dark band preceding B3, but this interface may be identified with confidence by lowering the monitor gain. B3 may be identified along the interval  $y = 0.0\text{cm}$  to  $y = +0.3\text{cm}$ , although the dark to bright transition is not as distinct. B2 can be identified from  $y = -0.5\text{cm}$  to  $y = +0.8\text{cm}$  with a fair amount of confidence and with the aid of low gain. Although the bright to dark transition in this range is not as distinct, it is adequately visible.

Significant Artifact: The diffuse patches within the lumen from  $X = 2.0\text{cm}$  to  $X = 2.5\text{cm}$  are the result of reverberations from the bright reflectors to the left of this area. The apparent gaps in B4 at  $y = 0.0\text{cm}$  to  $y = +0.4\text{cm}$  probably do not represent actual "holes" in the interface but are probably the result of a misaligned transducer. Gain settings could be considerably lower and if so, would probably reduce the multiple reverberations present within the lumen.

Figure 29 B-mode Image of Right Common Carotid

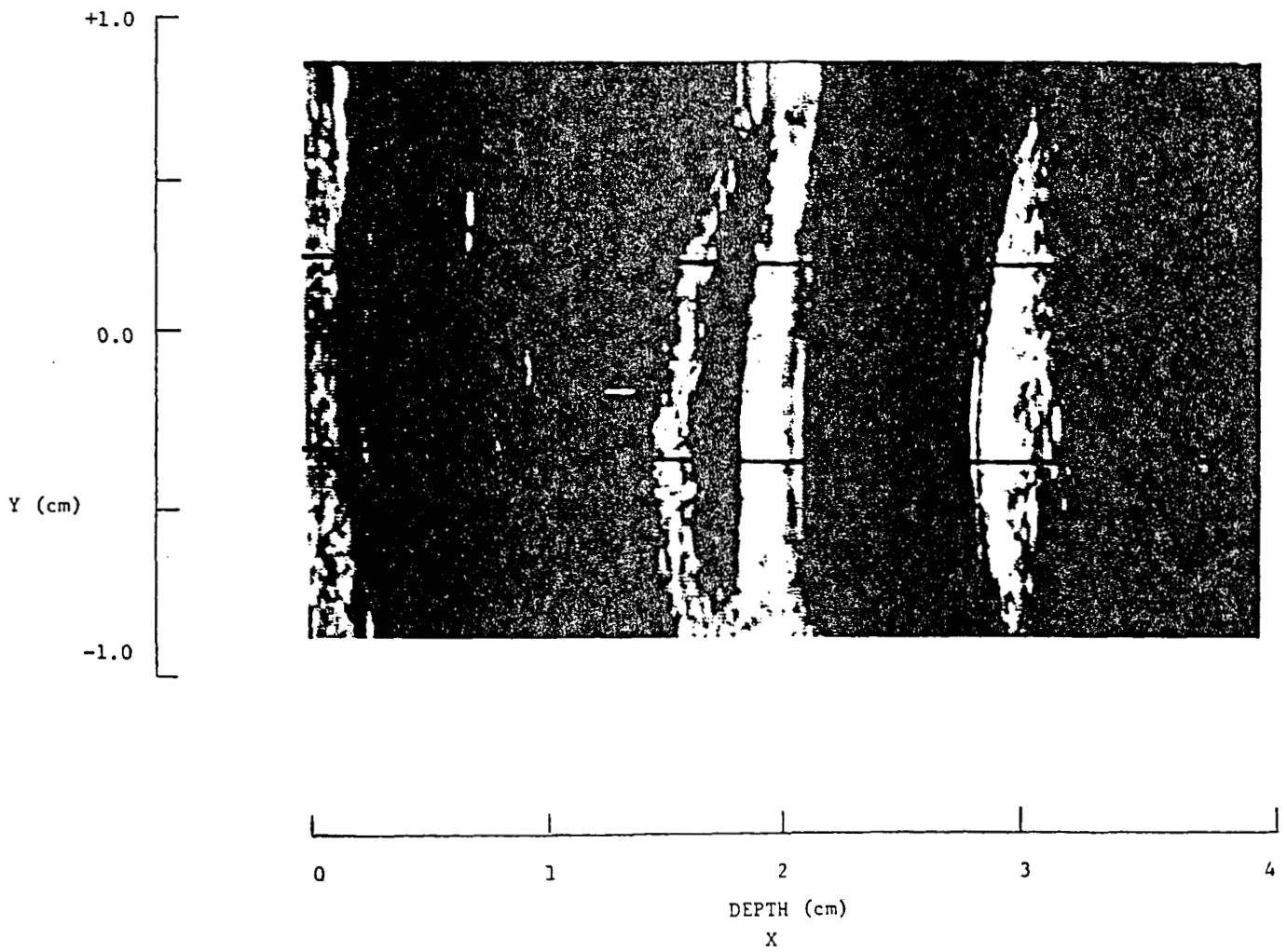





Figure 30 B-mode Image of Right Common Carotid: Detail of B-mode Image



Exercise 6 Right Common Carotid: Figures 31 and 32

Site: Right Common Carotid Artery

Anterior Wall Depth: X= 1.2cm

Posterior Wall Depth: X = 2.0cm

Cursor Placement: The cursor should be located at  $y = +0.5\text{cm}$  rather than  $y = +0.8\text{cm}$ .

Anatomical Landmark: Origin of the bulb is not identifiable. This suggests an interrogation angle other than the optimal (anatomical) angle, most probably the anterior angle. Origin of bulb should be located at  $y = +0.5\text{cm}$  and marked at this vertical location by the sonographer.

Posterior Wall: B4 is well visualized from  $y = -0.5\text{cm}$  to  $y = +0.5\text{cm}$ . The dark band to the right of B4 is moderately good and permits B5 to be easily identified over this interval. By reducing the brightness of the image monitor when marking B5, this boundary will be more clearly delineated. Sonographer alignment is excellent for the posterior wall.

Anterior Wall: B3 is well visualized from  $y = -0.5\text{cm}$  to  $y = 0.0$ . Above this segment, reasonable estimates of the location of B3 can also be made. The dark band which frequently appears to the left of B3 is fairly clear from  $y = -0.5\text{cm}$  to  $y = 0.0\text{cm}$  but becomes diffuse when moving upward. B2 can be approximated fairly well from  $y = -0.5\text{cm}$  to  $y = 0.0$  but becomes less certain as one moves upward. Anterior wall appears to be considerably thicker than the posterior wall.

Significant Artifacts: Diffuse bright regions located within the lumen between  $y = 0.0$  and  $y = +0.8\text{cm}$  and near  $y = -1.0\text{cm}$  are due to weak reflections of side lobes of the ultrasound beam from the lateral walls of the vessel.

Speckle adds apparent texture to both the posterior and anterior walls.

Figure 31 B-mode Image of Right Common Carotid

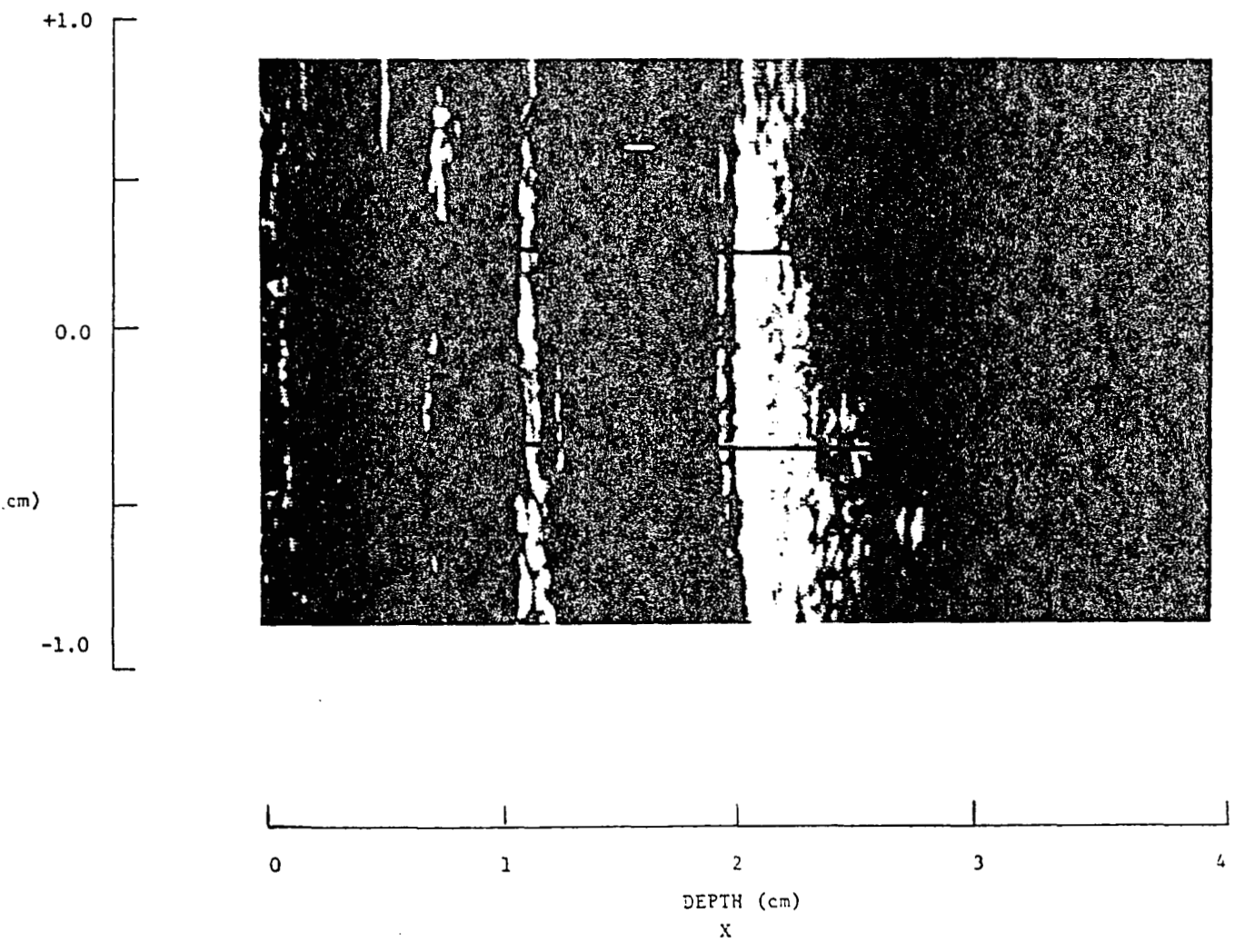



Figure 32 B-mode Image of Right Common Carotid: Detail of B-mode Image



Exercise 7 Right Common Carotid: Figures 33 and 34

Site: Right Common Carotid Artery

Anterior Wall Depth: X = 2.5cm

Posterior Wall Depth: X = 3.5cm

Cursor Placement: The cursor is correctly positioned at Y = +0.5cm.

Anatomical Landmark: The origin of the bulb in this image is not distinct, but it appears to be located slightly below the cursor position at Y = +0.1cm. The fact that the landmark is not clearly visible suggests that the transducer was not held at the optimal angle.

Posterior Wall: B5 is clearly visible from Y = +1.0cm to Y = -1.0cm. Although there is not an echo-free region preceding B5, there is a distinct "dark" to bright transition making it possible to make measurements of B5 with confidence. In this image the intima + media region, which is typically dark, is filled with echoes--some of which are fairly bright. Although there is not a thin, bright line representative of B4, B4 can be identified as the left edge of this echogeneous region from Y = +0.8cm to Y = -1.0cm. These echoes between B4 and B5 and the fact that the distance between B4 and B5 appears greater than usual suggests the presence of material not typically found within the artery wall. For example, the image may indicate some beginning stages of disease.

Anterior Wall: B2 and its characteristic bright to dark transition is clearly visible from Y = +0.6cm to Y = -1.0cm. Measurements of this interface may be made with confidence. There is a distinct, bright line and a dark to bright transition representative of B3 from Y = +0.6cm to Y = 0.0cm. The brightness of this interface compared to typical images of B3 is the result of some apparently highly reflective matter within the intima layer. There is also much echogenic matter between B2 and B3 within the intima + media layer. Measurements for B3 may be made on the right edge of this echogenic layer from Y = 0.0cm to Y = -1.0cm. In this region measurements of B3 are made on the right side of an echo because of the absence of the typical dark to bright transition. The highly reflective nature of the tissues in this wall suggest (as was the case for the posterior wall) the possibility of beginning disease in this artery.

Figure 33 B-mode Image of Right Common Carotid


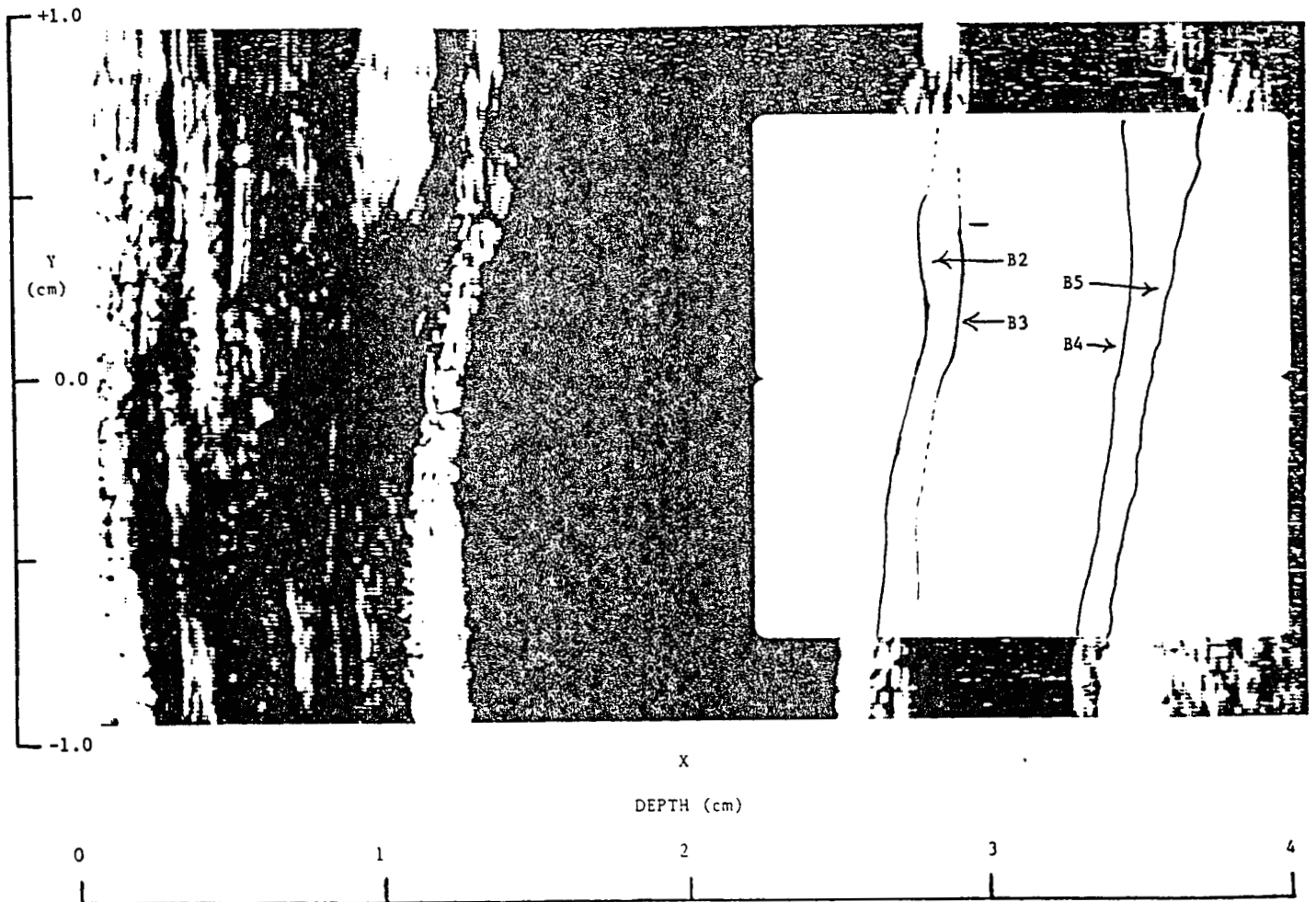


Figure 34 B-mode Image of Right Common Carotid: Detail of B-mode Image



Exercise 8 Right Internal Carotid: Figures 35 and 36

Site: Right Internal Carotid

Anterior Wall Depth:  $X = 1.7\text{cm}$  (at  $y = 0.0\text{cm}$ )

Posterior Wall Depth:  $X = 2.4\text{cm}$  (at  $y = 0.0\text{cm}$ )

Cursor: The cursor is properly placed at the superior arc of the flow divider located at  $y = -0.5\text{cm}$ .

Anatomical Landmark: The superior arc of the flow divider is visible and located at  $y = -0.5\text{cm}$ . This is the proper vertical placement.

Posterior Wall: The internal carotid begins at  $y = -0.5\text{cm}$  and extends upward. Although the posterior wall is visible from  $y = -0.5\text{cm}$  to  $y = 0.0\text{cm}$  the characteristic bright line for B5 is not present. Lowering the monitor brightness may give a smooth dark to bright transition from which a few measurements of B5 may be made. There is no B4 visible within the area of measurement except at the vertical position of the cursor,  $y = -0.5\text{cm}$ . B4 is visible below the area of measurement because of an apparent lesion which is located just below the tip of the flow divider in the bulb. It should be noted that cases may arise where lesions appear outside the site of measurement as it does in this image.

Anterior Wall: As with B5 there is not a distinct bright line representative of B2. There is a rough boundary which separates the anterior wall from the lumen and measurements of B2 may possibly be made along this interface from  $y = -0.5\text{cm}$  to  $y = +0.1\text{cm}$ . These measurements, however, may be of a low confidence level. B3 is not visible in this image of the interval.

Significant Artifact: Speckle adds much texture to both B2 and B5. Both walls appear to be missing above  $y = 0.0\text{cm}$ . This is because the artery begins to curve away from the skin surface at this point, and sound is greatly attenuated in this region.



Figure 35 B-mode Image of Right Internal Carotid

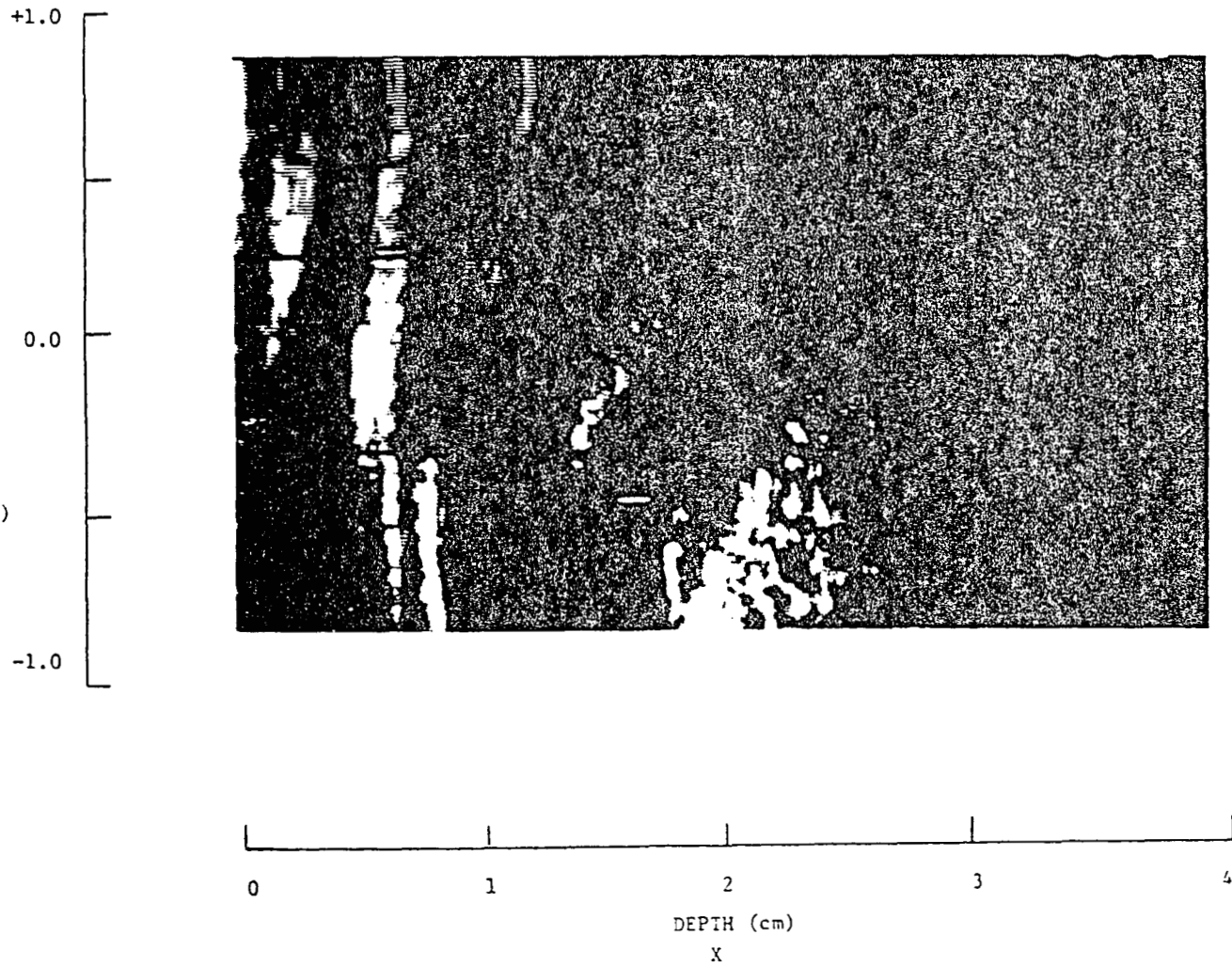



Figure 36 B-mode Image of Right Internal Carotid: Detail of B-mode Image



## Exercise 9 Left Common Carotid: Figures 37 and 38

Site: Left Common Carotid

Anterior Wall Depth: X = 1.5cm

Posterior Wall Depth: X = 2.5cm

Cursor: The cursor's vertical screen placement is correct at  $y = -0.5\text{cm}$ .

Anatomical Landmark: The origin of the bulb is visible not in the anterior wall but on the posterior wall. The origin appears to be located at  $y = -0.2\text{cm}$ .

Posterior Wall: B5 is clearly visible from  $y = -0.4\text{cm}$  to  $y = +0.4\text{cm}$ . Within this range the interface is distinct and continuous, and measurements may be made with confidence. Above the range B5 is less distinct; ( $y = +0.4\text{cm}$  to  $y = +0.8\text{cm}$ ) however, measurements may still be made. B4 is also visible, although this boundary is not as distinct. B4 could be identified from  $y = 0.0\text{cm}$  to  $y = +0.4\text{cm}$ .

Anterior Wall: B2 can be identified from  $y = -0.5\text{cm}$  to  $y = +0.5\text{cm}$ . Although there is not a continuous dark band to the right of B2, there is a distinct bright to "dark" transition along the interface and the measurements may be made with a fair amount of confidence. B3 is visible, although not continuous, from  $y = -0.7\text{cm}$  to  $y = +0.3\text{cm}$ . In the middle of the image B2 and B3 appear to be adjacent (no dark band between). Turning down the monitor gain may make it easier to identify B3 at this point.

Significant Artifact: There appear to be gaps in B3, although this is probably not the case. This is probably the result of slight angle changes in the transducer. At the top of the image in the middle of the artery is an echo which suggests that there is some structure within the lumen. This is probably caused by misalignment of the transducer.

Figure 37 B-mode Image of Left Common Carotid


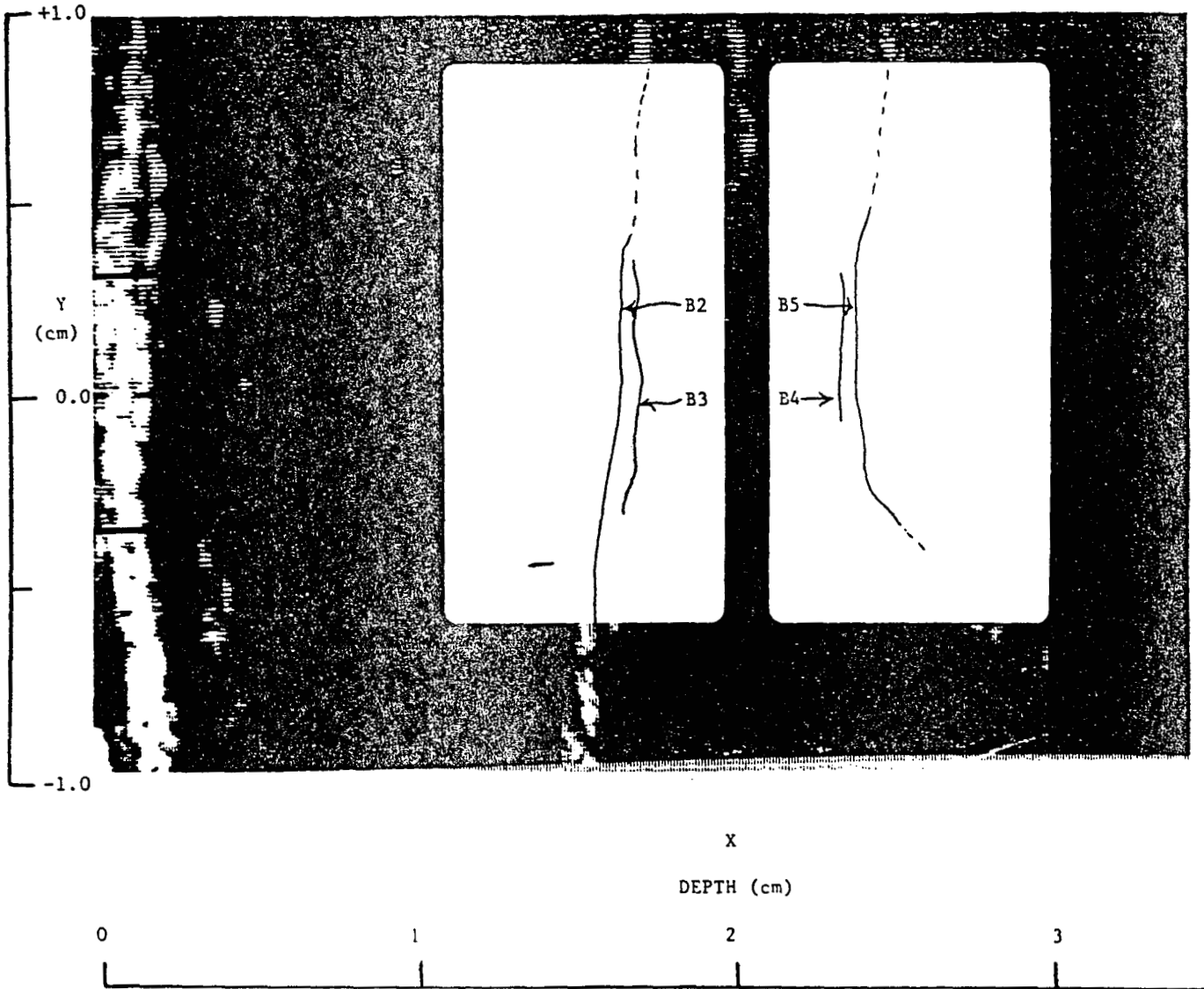


Figure 38 B-mode Image of Left Common Carotid: Detail of B-mode Image



Exercise 10 Left Common Carotid-Optimal: Figures 39 and 40

Site: Left Common Carotid-Optimal

Anterior Wall Depth: X = 1.5cm

Posterior Wall Depth: X = 2.5cm

Cursor: Correctly placed in the lower third of the screen at y = -0.5cm. Ideally positioned in the center of the artery.

Anatomical Landmark: The origin of the bulb is visible on the posterior wall and appears to be located at y = -0.2cm. Ideally it should be placed a little lower (y = -0.5cm); however, the vertical screen placement is adequate for proper measurement of the common carotid artery.

Posterior Wall: B5 is clear and distinct and may be easily identified from y = +1.0cm to y = -0.3cm. Below this region, from y = -0.3cm to y = -1.0cm, B5 is slightly visible, and with the aid of low monitor gain, identification of the interface may be made in this area as well. Although there isn't a characteristic dark band to the left of the boundary, B5 is adequately bright and distinct so that confident measurements may be made. B4 is clearly visible and, except for an apparent gap (located at y = -0.3cm), it is smooth and continuous. Confident measurements may be made of B4 from y = +1.0cm to y = -0.6cm. The echoes which appear within the media suggest that the sonographer's gain may have been relatively high. (Structure within the media is being picked up by the ultrasound system because of the higher gain.)

Anterior Wall: A thin bright line is visible for B2 from y = +0.6cm to +0.1cm and again from y = -0.2cm to y = -0.5cm. Above, below, and in between these two regions the location of B2 is unclear. Because of the apparent "smear" of B2, measurements of the interface may be made more confidently by lowering the monitor gain. Although B3 appears jagged and discontinuous, measurements may be made with a fair amount of confidence from y = +0.6cm to y = -0.5cm.

Significant Artifact: The apparent gaps in B2, B3 and B4 are probably the result of slight angle changes between the transducer beam and the artery wall.

Figure 39 B-mode Image of Left Common Carotid-Optimal

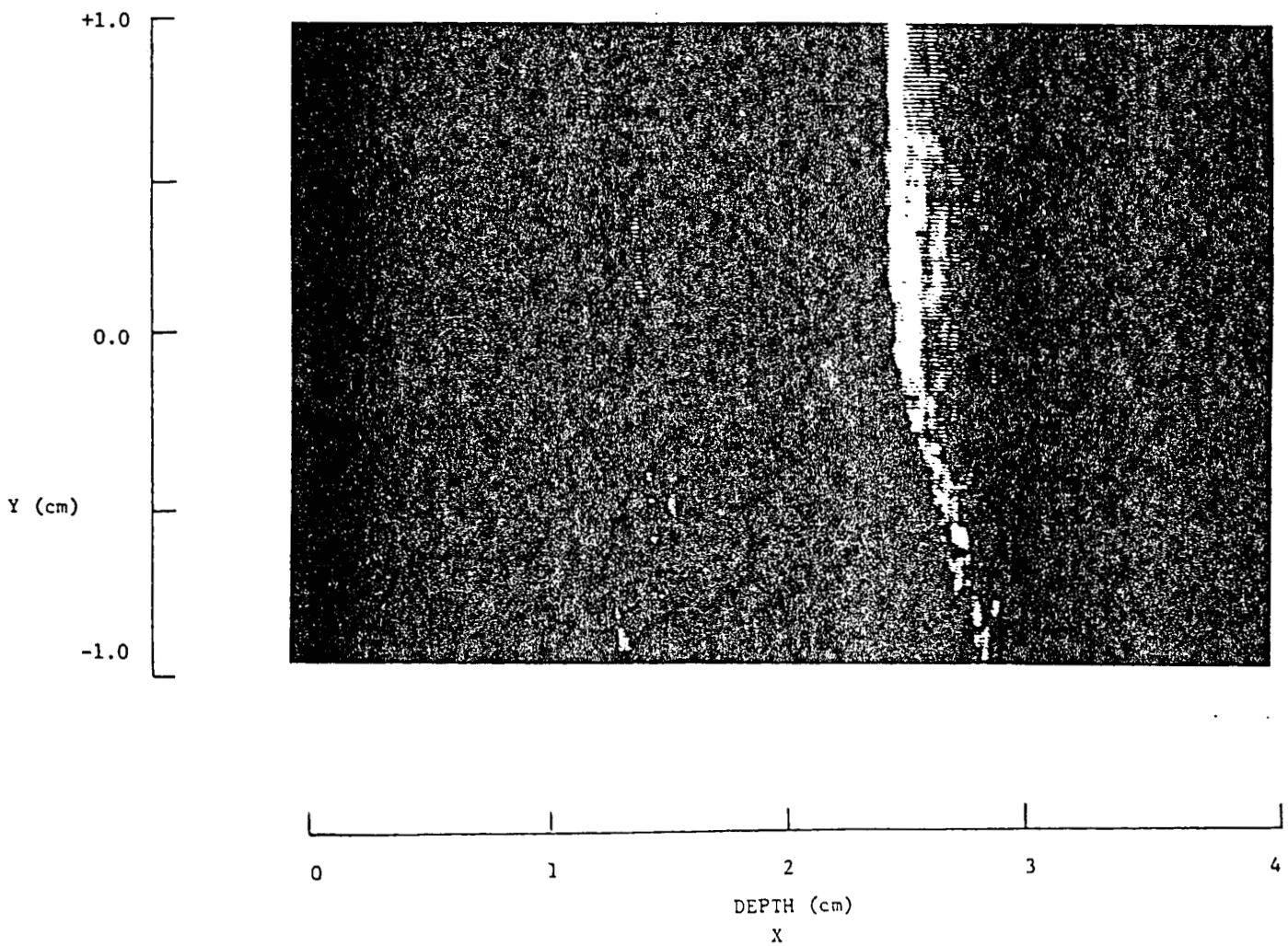



Figure 40 B-mode Image of Left Common Carotid-Optimal: Detail of B-mode Image





Exercise 11 Left Carotid Bulb: Figures 41 and 42

Site: Left Carotid Bulb

Anterior Wall Depth: X = 0.8cm

Posterior Wall Depth: X = 1.8cm

Cursor: The cursor is correctly placed at  $y = -0.4\text{cm}$ . Anatomically, it is positioned at the superior arc of the flow divider. The cursor's vertical position on the screen is ideal since it locates the area of measurement in the middle third of the screen.

Anatomical Landmark: The tip of the flow divider is clearly visible and is located at  $y = -0.4\text{cm}$ .

Posterior Wall: B5 is not very distinct; however, turning down the monitor brightness may aid in making measurements from  $y = -0.3\text{cm}$  to  $y = +0.5\text{cm}$ . B4 is not visible in this image.

Anterior Wall: B2 can be fairly well identified at the point of a bright to dark transition from  $y = -1.0\text{cm}$  to  $y = +0.6\text{cm}$ . As with B5, turning down the brightness may cause B2 to appear smoother and more distinct and allow measurements to be made with a greater degree of confidence. B3 can not be seen in this image.

Significant Artifact: Speckle as well as the curvature of the bulb add apparent texture to both B2 and B5.

Figure 41 B-mode Image of Left Carotid Bulb

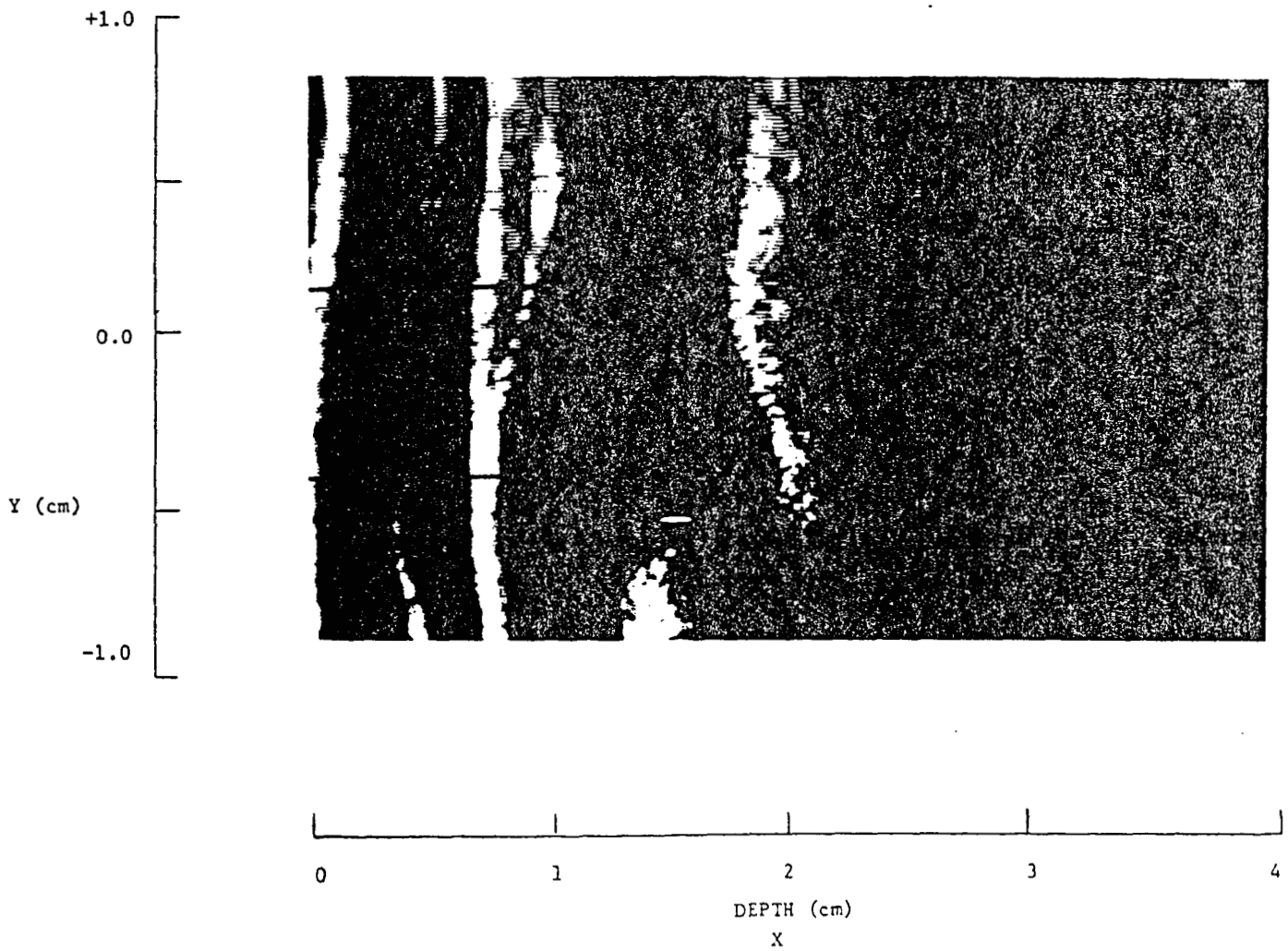
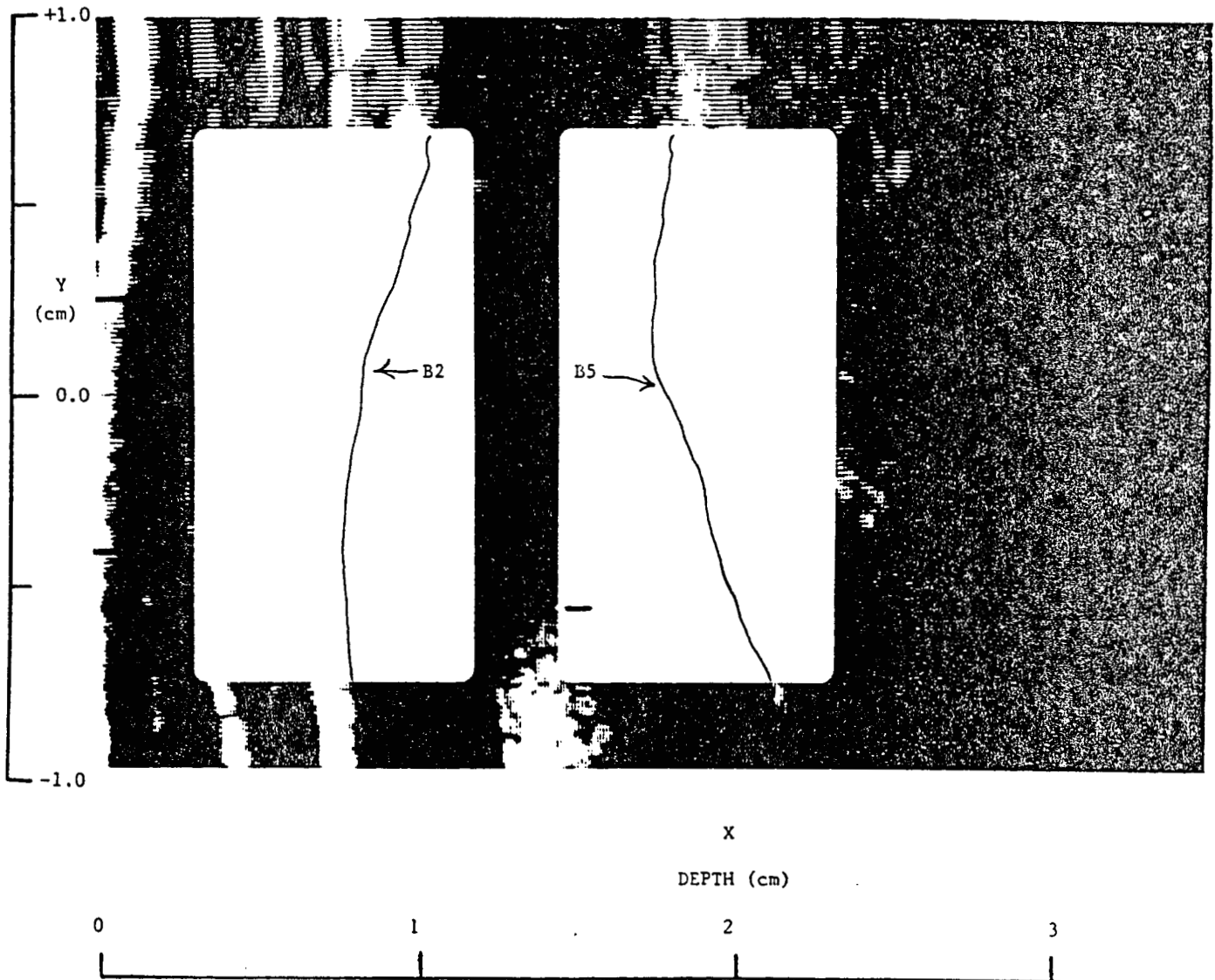


Figure 42 B-mode Image of Left Carotid Bulb: Detail of B-mode Image



Exercise 12 Left Carotid Bulb: Figures 43 and 44

Site: Left Carotid Bulb

Anterior Wall Depth: X = +0.5cm

Posterior Wall Depth: X = +2.2cm

Cursor Placement: The cursor is located at a correct vertical position of y = -0.5cm, at the tip of the flow divider.

Anatomical Landmark: The tip of the flow divider is clearly visible and is located at Y = -0.5cm and horizontally at X = 2.0cm.

Posterior Wall: B5 can be measured with relative confidence along two different intervals: from Y = +1.0cm to Y = +0.3cm and from Y = -0.1cm to Y = -0.8cm. Measurement along these intervals is aided by turning down monitor brightness. In the center of the image, from Y = +0.2cm to Y = -0.1cm, the posterior wall is not visible because of an artifact known as shadowing. B4 is visible from Y = +0.2cm to Y = +0.7cm. Although there is not a distinct, thin echo for B4, the band of low level echoes preceding B5 suggests the presence of material different from the lumen and it is possible to measure B4. The overall image gain appears low, and because these low level echoes are visible it suggests the presence of something abnormal (i.e., beginning lesion, fatty streak etc.). In the lower portion of the image, B4 is not clearly visible.

Anterior Wall: There is a thin, bright echo followed by a slightly visible bright to dark transition representing B2. By turning down the monitor brightness, this bright to dark transition may be more visible and B2 may be identified from Y = +1.0cm to Y = -0.7cm. As with the posterior wall, the typically dark band between 2 & 3 (or 4 & 5 on the posterior wall) contains some low level echoes suggesting the presence of matter not normally visible within this intima + media layer. Even though these low level echoes are present, a dark to bright transition for B3 is still slightly visible from Y = +1.0cm to Y = +0.2cm. In the center of the image from Y = +0.2cm to Y = -0.1cm, an apparent lesion and its echogenic substance make it difficult to visualize a dark to bright transition for B3. In this area B3 should be marked just to the right of the lesion as this is a good approximation of the intima-blood interface. Below the point Y = -0.1cm B3 cannot be visualized.

Significant Artifact: This image is a good example of an artifact known as shadowing. The posterior wall appears to have a large gap in it making it impossible to measure B4 and B5 in that particular area. Shadowing is typically the result of highly reflective or absorptive tissues through which very little or no sound passes. The effect is a blocking out or shadowing of any subsequent tissues in that path of the sound. In this case, the lesion on the anterior wall has apparently reflected (or absorbed) most of the sound energy so that no sound reaches the posterior wall. Therefore, neither the posterior wall nor the tissue following it are visible. Shadowed areas often indicate the presence of possible lesions preceding them, but nothing can be concluded about the shadowed tissues.

Figure 43 B-mode Image of Left Carotid Bulb





Figure 44 B-mode Image of Left Carotid Bulb: Detail of B-mode Image



Exercise 13 Left Carotid Bulb: Figures 45 and 46

Site: Left Internal Carotid Artery

Anterior Wall Depth: X = 1.6cm

Posterior Wall Depth: X = 2.7cm

Cursor Placement: The cursor is improperly placed. It should be placed at the superior arc of the flow divider which is located at  $y = +0.4\text{cm}$ .

Anatomical Landmark: The tip of the flow divider is clearly visible at  $y = +0.4\text{cm}$ . This is the proper vertical screen placement.

Posterior Wall: B4 is visualized from  $y = -0.5\text{cm}$  to  $y = 0.0\text{cm}$ . The dark band following B4 is distinct and therefore permits B5 to be easily identified from  $y = -0.5\text{cm}$  to  $y = +0.4\text{cm}$ . Lowering the monitor brightness will eliminate the fuzziness in the dark band from  $y = -0.5\text{cm}$  to  $y = -0.1\text{cm}$  making it even easier to identify B5.

Anterior Wall: B3 is not easily identified. Although some diffuse patches appear just to the left of the artery lumen, there is no distinct dark band following B2. Therefore, B3 could not be identified with much confidence. It should be noted, however, that turning down the monitor brightness may eliminate some of the diffuseness leaving brighter portions of B3 which may then be identified. B2 is easily identified from  $y = -0.3\text{cm}$  to  $y = +0.4\text{cm}$ . Just above and below this range it may be identified fairly well by turning down the monitor brightness.

Significant Artifact: The weak echoes appearing within the lumen around X = 2.0cm are artifact resulting from multiple reverberations between the two bright lines located at X = 1.3cm and X = 2.7cm.

A - 38

Figure 45 B-mode Image of Left Internal Carotid

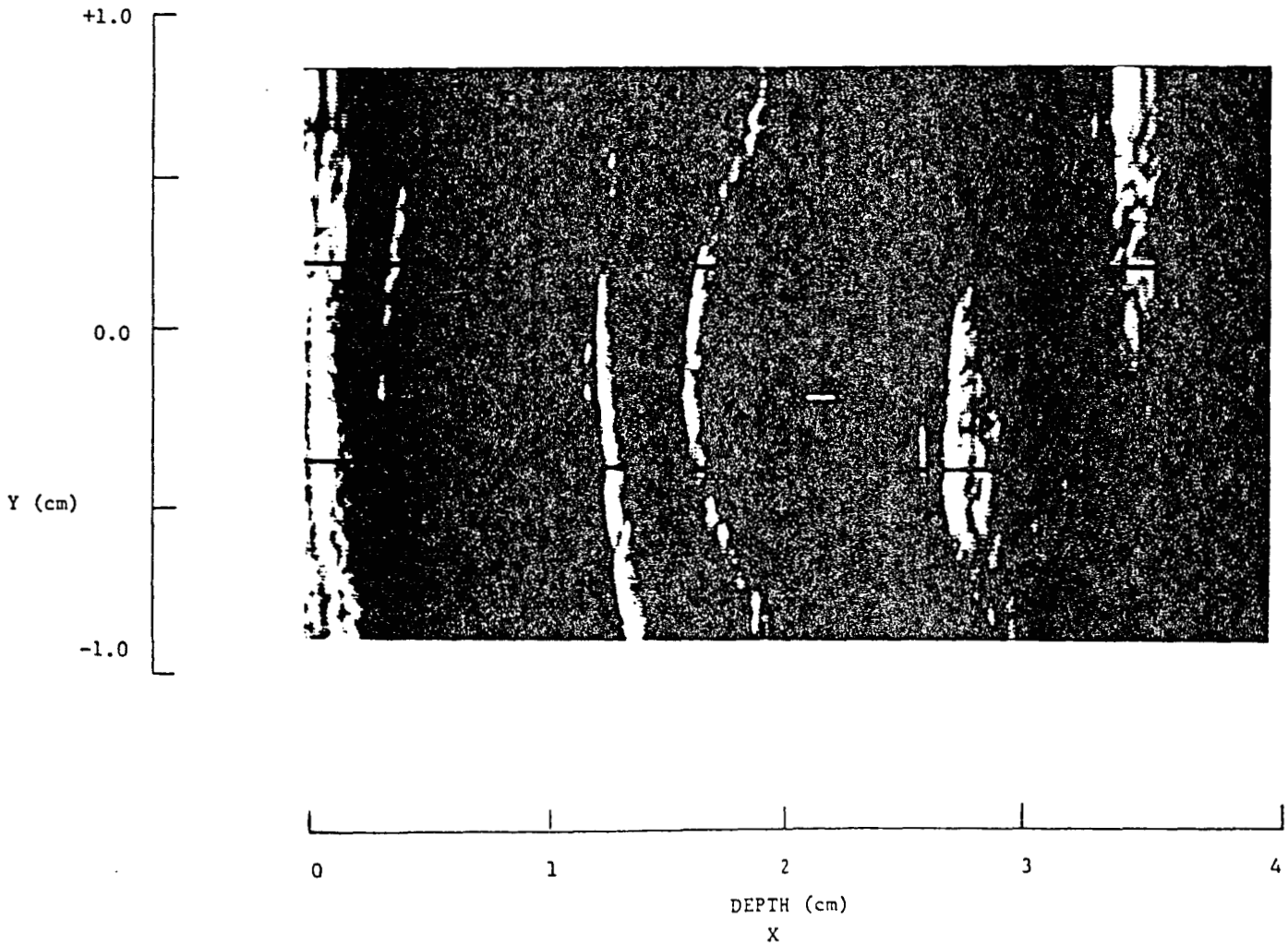
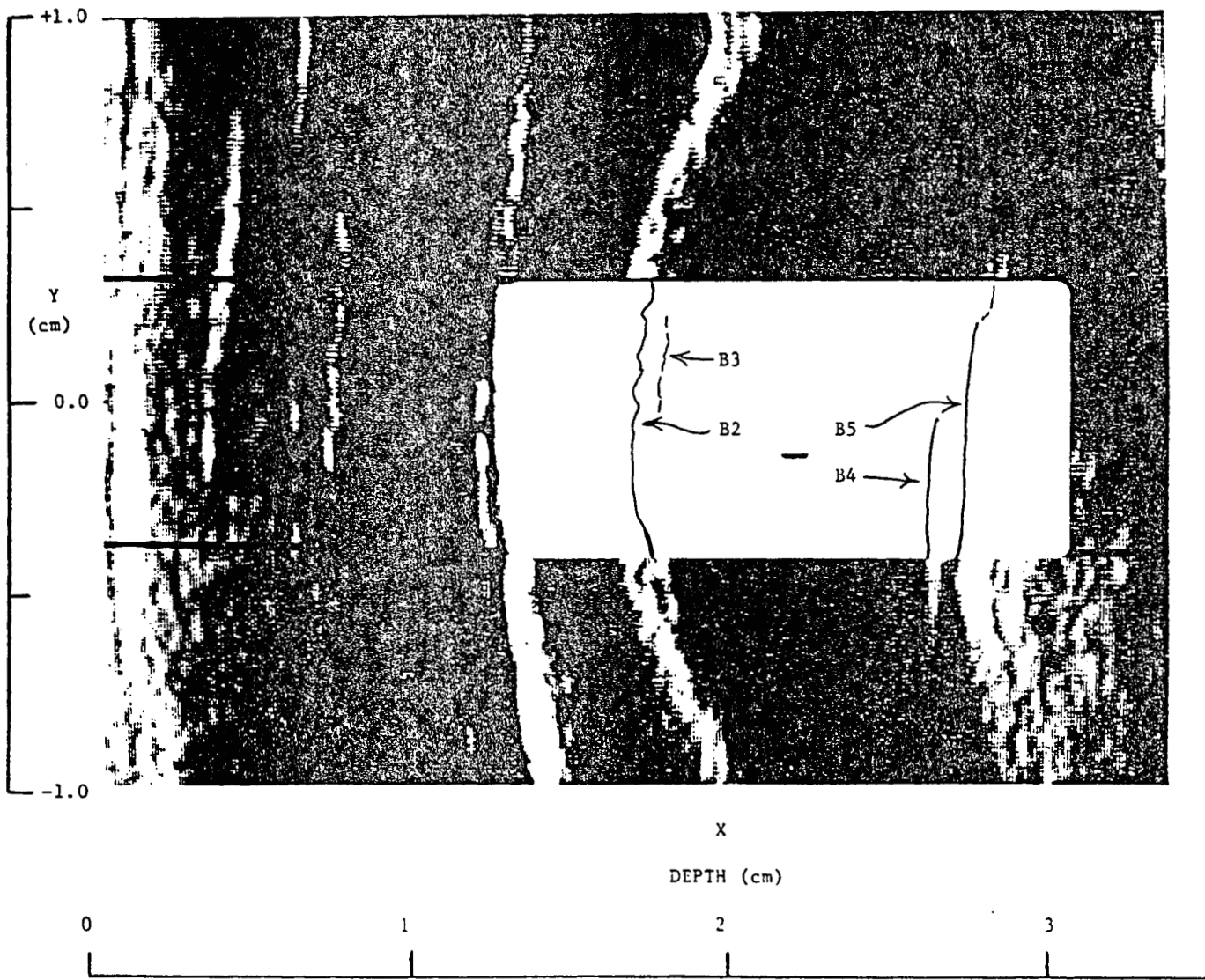




Figure 46 B-mode Image of Left Internal Carotid: Detail of B-mode Image



APPENDIX II: READING LIST

- "The Language of Anatomy"  
From: Gardner, W.D. & Osburn, W. A. (1973) Structure of the Human Body. (2nd ed.)  
Philadelphia: W.B. Saunders Company.
- "Angiology"  
From: Williams, P.L. and Warwick, R., eds. (1980) Gray's Anatomy. (36th ed)  
Philadelphia: W.B. Saunders Co.
- "Blood Supply to the Head and Neck"  
From: Fried, L.A. (1976) Anatomy of the Head, Neck, Face, and Jaws. Philadelphia:  
Lea & Febiger.
- "Systemic and Pulmonary Circulations"  
From: Underhill, S.L., Woods, S.L., Sivarajan, E.S. and Halpenny. C.J., eds. (1982)  
Cardiac Nursing. Philadelphia: J.B. Lippincott Co.
- "Pathogenesis of Atherosclerosis"  
From: Cardiac Nursing.
- "The Carotid Plaque"  
From: Robicsek, F. Ed. (1986) Extracranial Cerebrovascular Disease Diagnosis and  
Management. NY: McMillan Publishing.
- Diagnostic Ultrasound, Principles, Instruments, and Exercises by Frederick W. Kremkau,  
Ph.D. Third Edition Publisher: W. B. Saunders Company Harcourt Brace Jovanovich,  
Inc.
- Chapter 1 from Diagnostic Ultrasound;  
Frederick W. Kremkau, Ph.D. 3rd edition.
- Chapter 2, pages 9-30 in Diagnostic Ultrasound.
- Chapter 2, pages 41-45 of Diagnostic Ultrasound.
- Chapter 3 of Diagnostic Ultrasound.
- Chapter 4 pages 105-114 and pages 130-137 of  
Diagnostic Ultrasound.
- "How a B-mode Image is formed - A Summary".
- Chapter 5 in Diagnostic Ultrasound.
- Article, "Artifacts in Ultrasound Imaging" (Kremkau & Taylor)
- Chapter 6 in Diagnostic Ultrasound. Skip Section 6.3.
- Chapter 7 in Diagnostic Ultrasound. Skip Section 7.3.
- Pignoli, P., Termoli, E., Poli, A., Oreste, P., Paoletti, R. (1986) "Intimal Plus  
Medial Thickness of the Arterial Wall: A Direct Measurement with Ultrasound  
Imaging." Circulation. 74 (6), 1399-1406.
- Fact Sheet on Heart Attack, Stroke, and Risk Factors.  
(1987) American Heart Association. Dallas, TX.
- Pages 132-143 "Coronary Artery Disease Risk Factors"  
From: Cardiac Nursing

Coronary Risk Factor Statement to the American Public.  
(1987) American Heart Association. Dallas, TX.

Grundy, S.M. (1986) Cholesterol and coronary heart disease. JAMA. 256 (20) 2849-2858.

Eron, Carol (1988) Young hearts. Science News. 134, 234-236.

Stamler, J., Wentworth, D. & Neaton, J.D. (1986) "Is the Relationship Between Serum Cholesterol and Risk of Premature Death From Coronary Heart Disease Continuous and Graded?" JAMA. 256 (20) 2823-2828.

Enos, W.F., Holmes, R.H. & Beyer, J. (1953) "Coronary Heart Disease Among United States Soldiers Killed in Action in Korea: A Preliminary Report." JAMA. 152, 1090-1093. (Reprinted 1986 JAMA 256 (20).

#### Articles of Interest

"High Resolution B-mode Ultrasound Scanning Methods in the Atherosclerosis Risk in Communities Study (ARIC)", M.G. Bond et al. Journal of Neuroimaging, Vol 1, No 2, May 1991, pages 68-73.

"High Resolution B-mode Ultrasound Reading Methods in the Atherosclerosis Risk in Communities (ARIC) Cohort, Ward A. Riley, et al. Journal of Neuroimaging, Vol 1, No 4, November 1991, pages 168-172.

"An Approach to the Noninvasive Periodic Assessment of Arterial Elasticity in the Young" Riley, Barnes and Schey. Preventive Medicine 13, 169-184 (1984).

"Ultrasonic Measurement of the Elastic Modulus of the Common Carotid Artery: The Atherosclerosis Risk in Communities (ARIC) Study". Accepted by Stroke, 1992.